

RESEARCH AND OBSERVATION ON CLINICAL AND THERAPEUTIC ASPECTS REGARDING TRANSMISSIBLE VENEREAL TUMOR IN DOGS

Muste A., Beteg F., Muste M., Stroe T., Lăcătuș R., Hodiș Loredana

University of Agricultural Science and Veterinary Medicine Cluj-Napoca
Faculty of veterinary Medicine, 3-5 Manastur Street, 400372, Cluj-Napoca,
Romania
aurel_muste@yahoo.com

Abstract

Transmissible venereal tumor, also known as infectious sarcoma or Sticker tumor, has a different incidence from one race to another although the range is known as a cosmopolitan character disorder. In our study. In our cases the incidence was 23%. The initial lesions are superficial, small pink to red, 1 mm to 3 mm diameter nodules can be observed, then multiple nodules fuse together forming larger, red, hemorrhagic, cauliflower-like, friable masses, that draws the owners attention. Tumors bleed easily and while becoming larger, normally ulcerate and become contaminated (Hoque, 2002). For this study two groups were used, the first group included 11 dogs, the second group 12 dogs, different race and age, all males, raised in freedom, with little socialization with other dogs. For the first group the treatment was made with vincristine sulfate at a dose of 0.025 mg/kg, i.v, administered weekly, for a period of 7 weeks. The second group was treated with vinblastine at a dose of 0,1 mg/kg i.v, administered weekly, for 6 weeks. The best results were with vincristine, 95%, while the results for the treatment with vinblastine were between 85-95%.

INTRODUCTION

Transmissible venereal tumor (TVT) , also known as Sticker sarcoma or infectious sarcoma, is a benign reticuloendothelial tumor of the dogs male or female (Smith, and Washbourn, 1998) but it can be observed in wild canide (Dominguez-Tejerina et al., 1996), sexually mature. Usually it is transmitted during mating (Calvet, 1983), and it is more prevalent in temperate climates (Rogers, 1997).

It is commonly observed in dogs that are in close contact one with another, or in stray and wild dogs that exhibit unrestrained sexual activity (Cangul, 2003 cited by Purohit G.N.,2009).

This are the explanation for the high incidence (Jain, et al. 2002) of sarcoma in the dogs, or other studies performed on dogs in the same condition.

MATERIALS AND METHODS

The studies were conducted in the Surgery Clinic and Pathology of Veterinary Medicine Faculty Cluj-Napoca, on 100 dogs from different breeds and ages (2-6 years), male and female. 23 (23%) were treated by chemotherapy. The history revealed different maintenance systems: 25 of them were free (stray dogs), 26 raised in semi-freedom, the meaning of this refers that the dogs had periodic contact with other stray dogs, the rest of them had owners and they were raised in a restricted area, the contact with other dogs was rare and short. For diagnosis, clinical exam (an individual exam chart was made), cytological and histological exams by imprints of the tumors, fine needle biopsy.

Chemotherapy was made by using two products Vincristine sulphate and Vinblastine. For checking the efficacy of these two products we took in study a number of 23 dogs (15 males and 8 females) divided in two lots: the first one included 11 dogs (7 males and 4 females) and treated with Vincristine sulphate at a dose of 0,025 mg/kg i.v, once a week, for 7 weeks.

The second lot included 12 dogs (8 males and 4 females) and treated with Vinblastine at a dose of 0,1 mg/kg i.v, administered weekly, for 6 weeks. At the beginning of treatment animals were evaluated clinically by checking the temperature, heart rate and respiratory, all being in normal parameters.

RESULTS AND DISCUSSION

Clinical signs vary according to the localization of the tumors. On our cases lesions were localized on the external genital organs, cranially on the glans penis in males, 8 cases (34,78%), (Figure 1) followed by preputial mucosa on 5 cases (21,73%), and on the bulbus glandis 2 cases (8,69%) (Figure 2). On some subjects we noticed the lesions at the beginning, when they are superficial and pink to red color, multiple nodules shape, with 1-4 mm in diameter, then in time this develop, rise and fuse together forming larger, red, hemorrhagic, cauliflower-like, friable tumor (Figure 3).

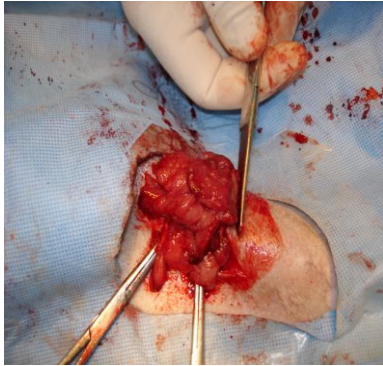


Figure 1. Tumor located on the glans penis

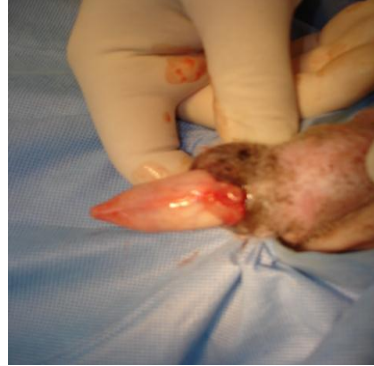

Figure 2. Bulbus glandis location aspect

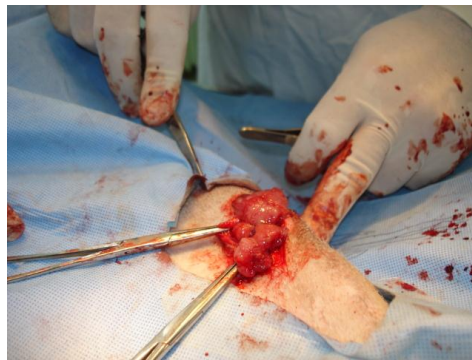


Figure 3. Cauliflower-like aspect

The tumoral mass can reach 5-8 cm in diameter which then progress deeper in the mucosa, and also outside it, often protruding from the prepuce, also observed by (Higgins, 1966) resulting the appearance of phimosis mentioned by authors (Mc Envoy, 1987), bleedings, ulcers and necrosis of the tumoral tissue. Tumors bleed easily, and when becoming larger, normally ulcerate and become contaminated (Hoque, 2002), hemorrhagic discharge at the prepuce, the blood has a dark color with a repulsing smell. The discharge can be confused at least at the beginning (before the tumoral growth) with urethritis, cystitis, or prostatitis (Rogers K.S., 1997). The involvement of regional lymph nodes is frequent in males with large tumors, in bitches this reaction may be absent. In our study the age of occurrence was between 2-6 years, which overlap with sexual maturity activity. In bitches the tumors have similar gross appearance as in male dogs and can be localized in the vagina (2 cases, 8,69%) or vulva (6 cases, 26,08%) deforming the region, protruding from the vulva and frequently causing a deformation of the perineal region. Because of repeted trauma, interference

with urine during micturition, the tissues suffer necrosis, they tear causing bleedings which in time leads to anemia, this state has been encountered in 2 of the bitches from the study. During our study we did not find other locations besides genital area.

Histologically tumoral cells are round to oval in shape in different mitotic phases, with hyperchromatic nucleus and one or two prominent nucleoli, aspects observed by (Gonzalez, et al. 2000; Singh, et al. 1996) (Figure 4). Remarkable is the presence of multiple clear cytoplasmic vacuoles, observed since 2004 (Tella, et al., 2004). Another aspect that should be mentioned is that the tumor mass increases, the cells become tightly packed and irregular in shape and fibroblasts appear, resembling features are also mentioned by other authors (Calvet, 1983; Kennedy, et al., 1977).

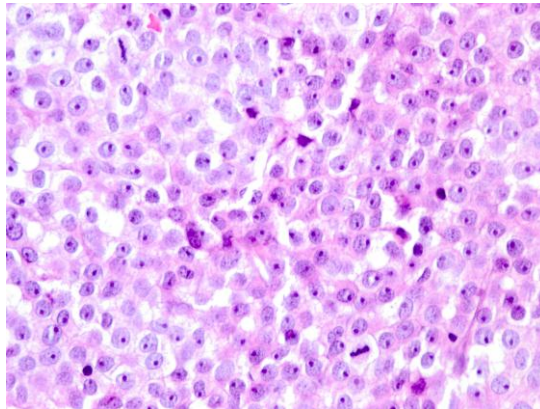


Figure 4. Tumoral cells with eosinophilic cytoplasm and hyperchromatic nucleus

Regarding the treatment, during time besides the surgical removal were used radiotherapy, immunotherapy, biotherapy and chemotherapy. In our study the animals treated with Vincristine sulphate had a 95% rate of success after 7 weeks from the first administration. The second lot was treated with Vinblastine but the results were not as efficient as the first one, the success rate was between 85-90% after 10-15 weeks from the first administration. During treatment the animals were kept under surveillance. At the end of the treatment blood samples were taken and haematological exams were made, to see if chemotherapy affects the blood values.

Table 1. Hematological aspects (average)

| TEST | Reference values | Vincristine | | Vinblastine | |
|--|------------------|----------------|-----------|----------------|-----------|
| | | Result average | % average | Result average | % average |
| Hemoglobin (g%) | 12-18 | 10,2 | 15 | 10,5 | 12,5 |
| PCV (%) | 37-55 | 32,38 | 12,5 | 32,93 | 11 |
| RBC ($\times 10^6/\mu\text{L}$) | 5.5-8.5 | 4,93 | 10,5 | 4,84 | 12 |
| WBC ($\times 10^3/\mu\text{L}$) | 6-17 | 5,22 | 13 | 5,07 | 15,5 |
| Neutrophils (%) | 60-70 | 47,7 | 20,5 | 50,7 | 15,5 |
| Lymphocytes (%) | 12-13 | 9,36 | 22 | 9,78 | 18,5 |
| Platelet Count ($\times 10^3/\mu\text{L}$) | 200-500 | 187 | 6,5 | 171 | 14,5 |
| Monocytes (%) | 3-10 | 2,62 | 12,5 | 2,58 | 14 |

Even if the registered values are at the lower end of the normal, this are not statistically significant. Three weeks after last administration the haematological values increased to normal values.

We mention that the administration was made in i.v solutions. Throughout treatment we monitored all the possible side effects especially those mentioned by authors as (Calvet, 1983; Withrow and McEwen 1996). For lots that we used Vincristine and Vinblastine we noticed that in the sixth and seventh week appetite decreased, the animals look tired, with muscle tonus decreasing. 10 days from last administration the animals recovered to normal status, without other side effects.

CONCLUSIONS

TVT is the most frequent neoplastic state of the external genital area in dogs, common in males and females, with similar evolution.

Incidence of this disorder in our study was 23%, the high incidence is assigned to the fact that most of them were stray.

The most effective and practical treatment in TVT is using Vincristine sulphate weekly in a dose of 0.025mg/kg in i.v solutions. In the last week of treatment, the animals from the study had muscle tonus decreased, lack of appetite, without any other side effects.

REFERENCES

- Calvet C.A., 1983. Transmissible venereal tumor in the dog. In: Kirk RW, ed. Current Veterinary therapy VIII. Philadelphia: WB Saunders Co, 413-415.
- Dominguez-Tejerina J.C., Pena V., Anel L., et al., 1996. Tumor venéreo transmisible. Arch Reprod Anim; (1): 42-47.
- Gandotra V.K., Chauhan F.S., and Sharma R.D., 1993. Occurrence of canine transmissible venereal tumor and evaluation of two treatments. Indian Vet.J.70:854-857.
- Gonzalez C.M., Griffey S.M., Naxdan D.K., Flores E., Cepeda R., Cattaneo G., Madewell B.R., 2000. Canine transmissible venereal tumor: a morphological and immunohistochemical study of 11 tumors in growth phase and during regression after chemotherapy. J. Comp. Pathol. 122:241-248.
- Higgins D.A., 1966. Observations on the canine transmissible venereal tumor as seen in the Bahamas. Vet.Rec. 79(3): 67-71.
- Hoque M., 2002. An update on canine transmissible venereal tumor. Intas Polivet.3 (II): 227-234.
- Jain A., Tiwari R.P., Tiwari S.K. and Awasthi M.K., 2002b. Clinical observations in TVT affected dogs treated with vincristine sulfate. Indian J. Anim.Reprod. 23 (I):71-72.
- Kennedy J.R., Yang T-J and Allen P.L., 1977. Canine transmissible venereal sarcoma: electron microscopic changes with time after transplantation. Br. J. Cancer 36, 375-385.
- Mc Envoy G.K., 1987. American Hospital Formulary Service Drug information. In: Bethesda, MD. American Society of Hospital and Pharmacists.
- Purohit G.N., 2009. Canine Transmissible venereal tumor: A Review. The Internet Journal of Veterinary medicine. Volume 6 Number 1.DOI: 10.5580/a6a.
- Rogers K.S., 1997. Transmissible venereal tumor. Comp Contin Educ Pract Vet. 19(9): 1036-1045.
- Singh J., Rana J.S., Sood N., Pangawkar G.R. and Gupta P.P., 1996. Clinico-Pathological studies on the effect of different anti-neoplastic chemotherapy regimens on transmissible venereal tumor in dogs. Vet.Res.Commun. 20(I): 71-81.
- Smith G.B., and Washbourn J.B., 1998. Infective sarcomata in dogs. Br. Med. J.2, 1346-1347.
- Tella M.A. Ajala O.O. and Taiwo V.O., 2004. Complete regression of transmissible venereal tumor (TVT) in Nigerian mongrel dogs with vincristine sulfate chemotherapy. Afr.J.Bio.Med.Res. 7 (3): 133-138.
- Withrow S.J. and McEwen E.G. 1996. Small animal clinical oncology. 2 ed. Philadelphia: WB Saunders Co.USA.