

CLINICAL, ULTRASOUND AND LABORATORY CHANGES IN CUSHING SYNDROME IN DOGS

Gabriela Marin (Ivaşcu), M.D. Codreanu, V. Nicorescu, Iuliana Codreanu, Maria Crivineanu

Faculty of Veterinary Medicine Bucharest, Romania, codveterinary@yahoo.com

Abstract

Dogs` adrenal pathology is dominated by Cushing syndrome, mostly by iatrogenic origin or neoplastic glandular lesions.

Clinical evaluation were performed following the classic screening protocol and additional hematological and biochemical investigations (liver/kidneys function), hormonal determinations (basal cortisol or after stimulation tests, i.e. suppression) and ultrasound exams. In our study were included 18 dogs with Cushing syndrome (hyperadrenocorticism). From clinical point of view the main registered clinical signs were bulimia, polyuria-polydipsia syndrome, abdominal ptosis, hepatomegaly, calcinosis and/or cutaneous hyperpigmentation, bilateral symmetrical alopecia). The biochemical blood profile registered changes (increased ALT and AST activity, hyperlipidemia, decreased serum urea levels, hyperglycemia) and urinary (diluted urine, proteinuria).

Ultrasound reveals in case of affected adrenal glands appears as distinct structures, flattened shape, appearance lobe, located cranio-medial kidney, caudal of the mesenteric and celiac artery and cranial of the renal artery and the right (lower) prior to renal vein and cranial right kidney. According to their topography, size and structure the ultrasound changes were very useful for the diagnosis of the diseases related to adrenomegaly and changing their echogenicity and echostructure.

Key words: *adrenal glands, Cushing syndrome, dogs.*

INTRODUCTION

The adrenal pathology in dog's pathology is mainly dominated by Cushing syndrome, in most cases by iatrogenic origin or tumoral glandular changes (Syme et al., 2001).

In dogs, Cushing syndrome with pituitary origin (center) is the most common cause of spontaneous Cushing, representing over 80% of cases (Feldman, 2005; Galac, 2010).

Cushing syndrome encompasses a variety of clinical and biochemical abnormalities resulting from chronic exposure to high concentrations of glucocorticoids, in addition with many clinical and parenchymatous functional changes.

In such cases if clinical changes are obvious, next step is the adrenal ultrasound evaluation, using higher transducers and functionally testes by dosing cortisol, basal, or using specific tests (ACTH stimulation/suppression with dexamethasone).

As in human medicine, canine hyperadrenocorticism (Cushing syndrome) has various pathophysiological origins but all share one common denominator, the chronic excess cortisol systemically.

MATERIALS AND METHODS

In our study were included 18 dogs with Cushing syndrome (hyperadrenocorticism), initially suspect by the specific clinical and paraclinical changes.

Clinical evaluations were performed following the classic screening protocol and additional hematological and biochemical investigations (liver/kidneys function), hormonal determinations (basal cortisol or after stimulation tests, i.e. suppression) and ultrasound exams (Witt and Neiger, 2004).

In Cushing's syndrome (hyperadrenocorticism), adrenal impairment is accompanied by morphological and eco-structural alterations, appreciable ultrasound method that ranks priority in terms of relevance and specificity (Hoerauf and Reusch, 1999; Wood at al., 2007; Codreanu et al., 2009). Adrenals ultrasound was performed using high frequency transducers (8 -18 MHz).

RESULTS AND DISCUSSIONS

From clinical point of view the main registered clinical signs were bulimia, polyuria-polydipsia syndrome, abdominal ptosis, hepatomegaly, calcinosis and/or cutaneous hyperpigmentation, bilateral symmetrical alopecia), results presented in Table 1.

The biochemical blood profile registered changes (increased ALT and AST activity, hyperlipidemia, decreased serum urea levels, hyperglycemia) in 68.75% and urinary (diluted urine, proteinuria) in 81.25%.

Was dosed the basal cortisol and then were given 2.2 IU / kg Cortrosyn, after which was dosed the cortisol, after administration (Gould et al., 2001; Bosje et al., 2002). Following dosing basal cortisol and cortisol after ACTH stimulation was possible to confirm Cushing (Cushing's syndrome), results are shown in Chart 1.

Table 1. Pooled data for establishing the diagnosis of Cushing syndrome

CLINICAL CHANGES	No. and % of patients		NOTES ON PHYSICAL EXAMINATION	No. and % of patients	
	No.	%		No.	%
Polyuria/ Polydipsia	18	100	Alopecia	10	55,5
Polyphagia	9	50	Dermatosis	4	22,2
Respiratory changes/dyspnea	3	16,6	Comedones	3	16,6
Abdominal ptosis	12	66,6	Cutaneous calcification	5	27,7
Dorsal bilateral alopecia	14	77,7	Decreased muscular tonus	10	55,5
Weakness	9	50	Hepatomegaly	7	38,8
Lethargy	10	55,5	Increased limphonodes	3	16,6
PARACLINICAL MAIN CHANGES					
<i>Biochemical altered parameters :</i> Alkaline Phosphatase: 284-584 U/l ALT: 66-134 U/l AST: 64-91 U/l Cholesterol: 744-980 mg/dl					
URINE EXAMINATION					
Specific gravity in all tested samples < 1,013					
ACTH STIMULATION TEST					
Excessive cortisol response in tested dogs after ACTH administration > 24,9 μ g/dl (24,9-33,6 μ g/dl)					

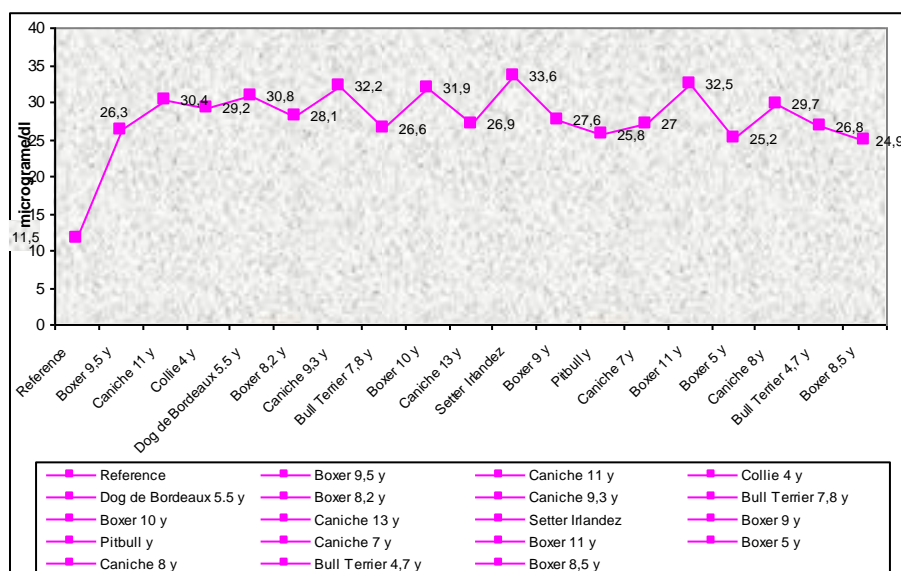
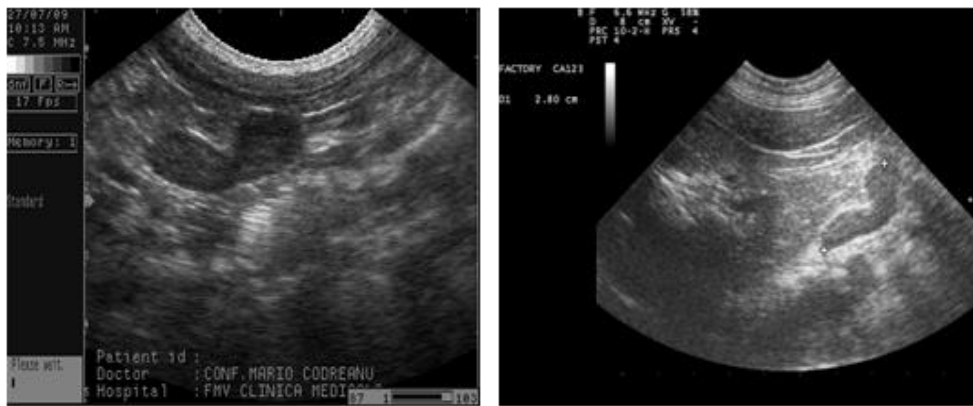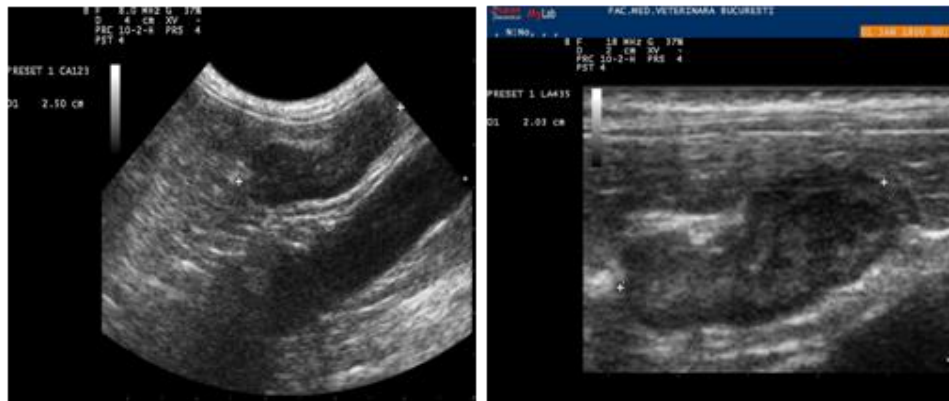


Chart 1. Results of cortisol level after stimulation (ACTH), which confirm the diagnosis of hyperadrenocorticism in selected dogs

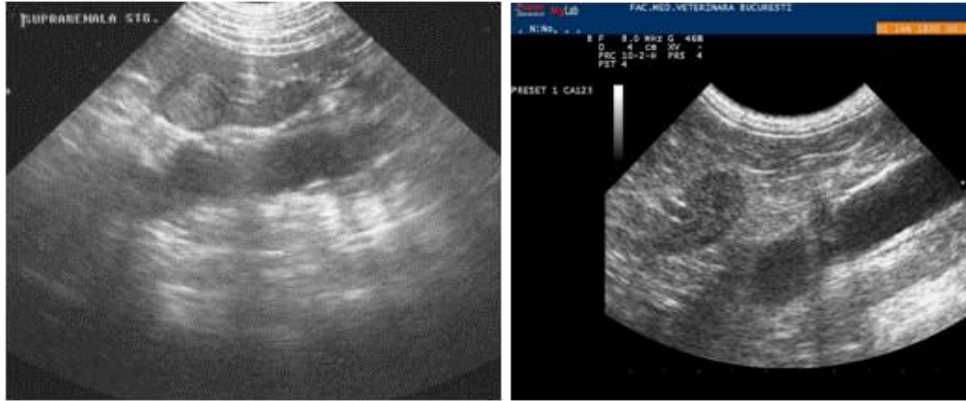Ultrasound reveals in case of affected adrenal glands appears as distinct structures, flattened shape, appearance lobe, located cranio-medial kidney, caudal of the mesenteric and celiac artery and cranial of the renal artery and the right (lower) prior to renal vein and cranial right kidney (Figures 1-6). In Cushing syndrome the most important ultrasound changes were represented by diffuse bilateral in 68.75% (Figures 1-4), unilateral (18.75%) adrenomegaly and local ultrasonographic changes of irregular shape, different echostructure and echogenicity in 12.5%, of nodular aspect (Figures 5-6).



Figures 1 - 2. Diffuse adrenomegaly - normal echostructure



Figures 3 - 4. Localised adrenomegaly-cortical-medular normal ratio



Figures 5 - 6. Nodular changes of different echostructure and echogenicity

CONCLUSIONS

In establishing and confirming the diagnosis of hyperadrenocorticism in dogs from our investigation and for recommending fair and effective therapeutic measures, we have performed very cautious anamnesis corroborating data with results of clinical examination, additional laboratory investigations, obtaining thus an insight into the context which seeks, accurate differentiation of this syndrome of different pathological processes similar events.

Increased levels of basal cortisol and the cortisol excessive response (statistically significant) after administration of ACTH in all dogs of group (from 24.9 to 33.6 $\mu\text{g} / \text{dl}$), confirm the diagnosis of hyperadrenocorticism. According to their topography, size and structure the ultrasound changes were very useful for the diagnosis of the diseases related to adrenomegaly and changing their echogenicity and echostructure.

When can be visualized both adrenal glands, and their size is relative similar, the most probably can be the expression of the hyperadrenocorticism, and when their size, echostructure and echogenicity is very different, the diagnosis with a high degree of accuracy, is adrenal tumor.

REFERENCES

- Bosje J.T., Rijnberk A., Mol J.A., Voorhout G., Kooistra H.S., 2002. Plasma concentrations of ACTH precursors correlate with pituitary size and resistance to dexamethasone in dogs with pituitary-dependent hyperadrenocorticism. *Domest. Anim. Endocrinol.*, 22, 201-210.
- Codreanu M. și col., 2009. Studiu privind importanța examenului ecografic în diagnosticul afecțiunilor suprarenalelor la câine, *Lucrări științifice Iași*, 52(11), 483-486.
- Feldman E., 2005. An update on the diagnosis of Cushing's Syndrome in Dogs. Conference at Wisconsin Veterinary Medical Association Convention, Madison, Wisconsin.
- Galac S., 2010. Recent developments in canine Cushing's syndrome. PhD Thesis, Utrecht University, Netherlands.
- Gould S., Baines E.A., Mannion P.A., Evans H., Herrtage E., 2001. Use of endogenous ACTH concentration and adrenal ultrasonography to distinguish the cause of canine hyperadrenocorticism. *J. Small Anim. Pract.*, 42, 113-121.
- Hoerauf A., Reusch C.E., 1999. Ultrasonographic characteristics of both adrenal glands in 15 dogs with functional adrenocortical tumors. *J. Am. Anim. Hosp. Assoc.*, 35, 193-199.
- Syme H.M., Scott-Moncrieff J.C., Thompson M.F., Snyder P.W., White M.R., Oliver J.W., 2001. Hyperadrenocorticism associated with excessive hormone production by an adrenocortical tumor in two dogs. *J. Am. Vet. Med. Assoc.*, 219, 1725-1728.
- Witt A.L., Neiger R., 2004. Adrenocorticotrophic hormone levels in dogs with pituitary-dependent hyperadrenocorticism following trilostane therapy. *Vet. Rec.*, 154, 399-400.
- Wood F.D., Pollard R.E., Uerling M., Feldman E., 2007. Diagnostic imaging findings and endocrine test results in dogs with pituitary-dependent hyperadrenocorticism that did or did not have neurologic abnormalities: 157 cases (1989-2005). *J. Am. Vet. Med. Assoc.*, 231, 1081-108.