

IS THE CHROMATIC PUPILLARY RESPONSE (CPR) A "FOOTHOLD" IN THE DIAGNOSIS OF OPHTHALMOLOGICAL AND NEUROLOGICAL DISORDERS?

Iuliana Ionașcu, Adina Bădicu – 6th year student

University of Agronomic Sciences and Veterinary Medicine of Bucharest, Faculty of Veterinary Medicine, Bucharest, Romania, driulianaionascu@yahoo.com, adyna_88@yahoo.com

Abstract

Recent studies have shown that a light stimuli of a certain intensity and wavelength can influence the pupillary response. The aim of this research is to evaluate the CPR and to establish its role in the differential diagnosis of ophthalmological and neurological disorders.

CPR is part of the patients' ophthalmological clinical examination protocol brought to the clinic of the Bucharest Faculty of Veterinary Medicine. These patients (dogs and cats) had one or more ophthalmological symptoms (progressive loss of vision, mydriasis, anisocoria, blindness) and/or neurological symptoms (nystagmus, torticollis, circling, ataxia, proprioceptive deficits).

CPR examination was performed in the darkroom, using the IRIS-VET device.

CPR is positive in healthy animals, represented by miosis.

Negative, delayed or incomplete CPR (mydriasis) to the red light (630 nm, 200 kcd/m²) reveals an impairment of the photoreceptor cells of the retina, lesions encountered in retinal detachments, retinal dysplasia or progressive retinal atrophy.

CPR absence to the blue light (480 nm, 200 kcd/m²) provides information about the optic nerve and retinal ganglion cells.

Negative CPR both to the red and blue light was present in glaucoma and optic chiasm disorders.

The study showed that CPR is a fast and easy method to differentiate between ophthalmological and neurological disorders.

Key words: *chromatic pupillary response, melanopsin, neurological disorders.*

INTRODUCTION

The pupillary light response (PLR) is a reflex that controls the diameter of the pupil, in response to the intensity of the light. It is an objective parameter in assessing the retinal, optic nerve and oculomotor nerve function. (Grozdanic, 2007)

Traditionally, clinical testing of PLR activity is performed with nonchromatic white light stimuli of different light intensities.

The pupil's response to light stimuli of a certain intensity and wavelength is chromatic pupillary response (CPR). The CPR was evaluated based on the response of the photoreceptors, the melanopsin-containing retinal ganglion cells and the optic nerve to the white, red and blue light stimuli.

The discovery of the melanopsin-containing retinal ganglion cells and their mediation of the PLR has allowed better understanding of the neural input to the PLR and the conditions of light stimulus affecting it. (Grozdanic, 2007)

The melanopsin-containing retinal ganglion cells represent a small subset (~1-3%) of the retinal ganglion cells.

They play a role in synchronization of the biological clock with the light-dark cycle, contribute to photic regulation of the hormone melatonin from the pineal gland. Recent information show that intrinsically photosensitive retinal ganglion cells (ipRGCs), using the photopigment melanopsin, respond directly to light to drive pupillary constriction. These cells project and innervate the superior colliculus and dorsal lateral geniculate nucleus, retinotopically organized nuclei mediating object localization and discrimination. Thus, ipRGCs can support spatial visual perception. (Ecker, 2012; Hattar, 2002; Kardon, 2009; Markwell, 2010)

The peak spectral sensitivity of the receptor is between 460 and 484 nm. (Grozdanic, 2007; Markwell, 2010)

Taking those information into consideration it is possible using PLR to differentiate diseases affecting the outer retina from those affecting the inner retina and optic nerve based on properties of the light stimuli, such as wavelength and intensity.(Grozdanic, 2007)

MATERIALS AND METHODS

The study was conducted on healthy patients, on patients with ophthalmological signs, and/or with neurological signs.

To rule out the possible presence of ocular and neurological disease, the healthy patients, with age between 3 months and 7 years, were carefully examined, using direct ophthalmoscopy, intraocular pressure measurement, and neurological exams.

The evaluation of CPR was performed using the IRIS-VET device (Biomed Vision Technologies). It tests the retina and optic nerve function based on the evaluation of spectral properties of the pupil light reflex and is

characterized by powerful light sources with very precise light intensity output (200 kcd/ m^2) and very precise wave lengths (ultra-bright red diode source – 630 nm; ultra-bright blue light diode source – 480 nm), which can be used to elicit different spectral components of the pupil light reflex (Figure 1).

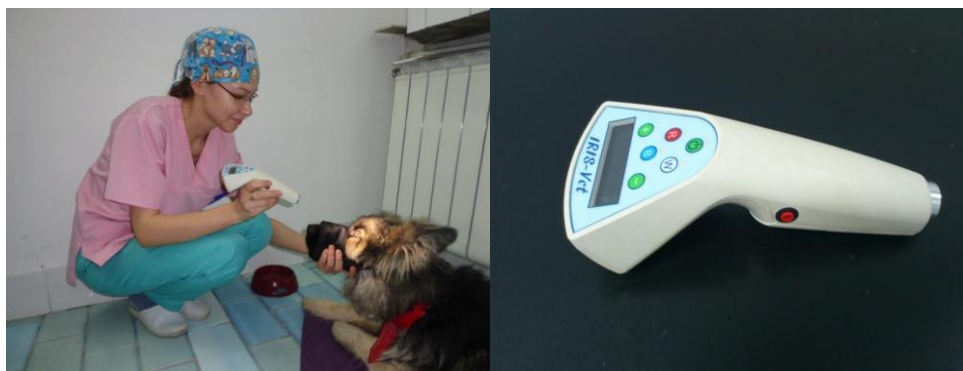

Figure 1. The IRIS VET device

The patients were examined in a dark room, after 15 seconds, in order to achieve the dark adaptation.

The right eye was illuminated using white light from a distance of 5 cm, for approximately 10 seconds and the pupillary changes were observed. If complete pupil constriction was achieved in less than 10 seconds, the light source was turned off. After 15 seconds, when dark adaptation is achieved again, the left eye was illuminated with white light from a distance of 5 cm and changes in the pupil diameter were observed.

After CPR to white light stimuli was assessed and after the dark adaptation was achieved, each eye was stimulated using red light stimuli (200 kcd/ m^2 , 630 nm) and blue light stimuli (200 kcd/ m^2 , 480 nm), following the above protocol.

The white light was used for the overall assessment of the eye, the red light provided information about the photoreceptors' (rods and cones) function, and the blue light assessed the ipRGCs and optic nerve function.

A normal CPR is represented by pupillary constriction to the light stimuli. Decreased or absent pupillary constriction when stimulated with red light revealed retinal damage. No response (mydriasis) to blue light was recorded when damage of the ipRGCs and optic nerve was present (Figure 2).

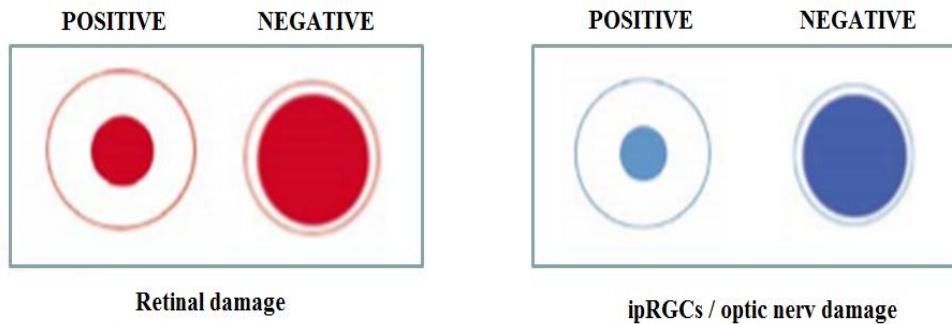


Figure 2. The CPR to red and blue light stimuli

After all pupillary responses were observed and recorded, we used the obtained results in combination with other parameters obtained during clinical examination and complementary tests to establish the final diagnosis.

Electroretinography was used to establish diagnoses of progressive retinal atrophy (PRA) in two dogs. The patients displayed a complete absence of retinal electrical activity during ERG recording.

Ultrasound confirmed the diagnosis of retinal detachment in all affected patients.

RMN was used to establish the diagnosis of hemorrhage located near the optic chiasm in one French Bulldog, age of 1 year, with no neurological or ocular signs, and with relatively normal CPR.

RESULTS AND DISCUSSIONS

All healthy patients presented miosis to all light stimuli.

The blind patients presented to the clinic with mydriasis of one or both eyes, anisocoria, absent pupillary light reflex, absent menace response, normal or increased intraocular pressure. The neurological signs of some of the patients included nystagmus, torticollis, circling, ataxia, proprioceptive deficits.

IRIS VET was used to differentiate between a neurological and an ophthalmological disorder in the first stage of the clinical examination and to guide the further diagnostic approach.

The fundus ophthalmoscopic examination revealed the diagnosis: retinal detachment. The pupil light reflex was usually incomplete, slow or sometimes absent (Figure 3).

Due to the photoreceptor (outer segments) damage, the photoreceptor-mediated pupil light response (red light) is usually absent, while melanopsin-mediated response (blue light) is present or decreased. Retinal detachment older than 1 month sometimes resulted in the complete loss of the red response and incomplete blue response.

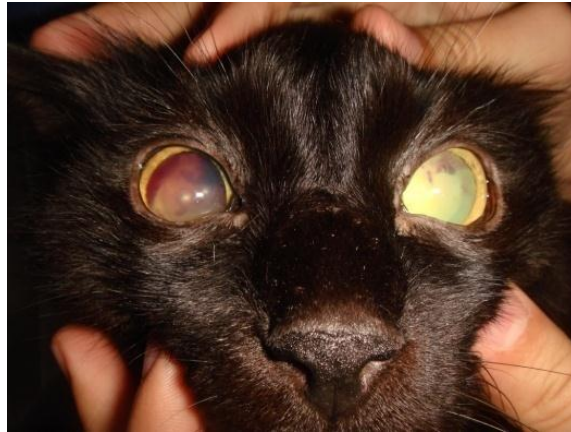

Figure 3. Retinal detachment in a cat – bilateral mydriasis

Progressive retinal atrophy is characterized by progressive loss of vision, hyperreflectivity of the tapetum lucidum (Figure 4). Stimulation of the pupil light reflex in PRA patients with red light does not provide any response (mydriasis). Stimulation with blue light provides immediate and complete miosis due to activation of melanopsin-containing retinal ganglion cells (ipRGCs).

PLR to blue light (melanopsin-mediated response) is usually normal in early retinal degeneration or decreased with pupillary escape in advanced retinal degeneration, which is suggestive of the inner retina structural and organizational remodeling and retinal ganglion cell degenerative changes. Electroretinography was used in 2 cases in order to confirm the diagnosis.



Figure 4. Progressive retinal atrophy in a dog (mydriasis, hyperreflectivity of the tapetum lucidum)

Glaucoma affects both the retina and the optic nerve. The patients had increased intraocular pressure (>20 mmHg), mydriasis and no PLR. In one case, the only clinical signs were increased intraocular pressure (27-30 mmHg) and mydriasis. Using CPR was crucial because it indicated an ophthalmological disease, specifically a retinal damage: the photoreceptor-mediated CPR (red light stimuli) was absent, while melanopsin-mediated CPR (blue light stimuli) was slightly decreased or with pupillary escape, indicating that it was not an inner retina or CNS disorder. An ultrasound was performed and the final diagnosis was retinal detachment with secondary glaucoma.

In secondary glaucoma, where the retinal and optic nerve function were damaged due to increased intraocular pressure and ischemia, CPR was absent (mydriasis).

Disorders manifested with blindness, anisocoria, mydriasis, blindness, normal or decreased CPR and without neurological signs were further investigated with RMN. The results confirmed neurological disorders such as: metastatic brain tumor, optic chiasm tumor or hemorrhages involving the optic chiasm (Figura 5).

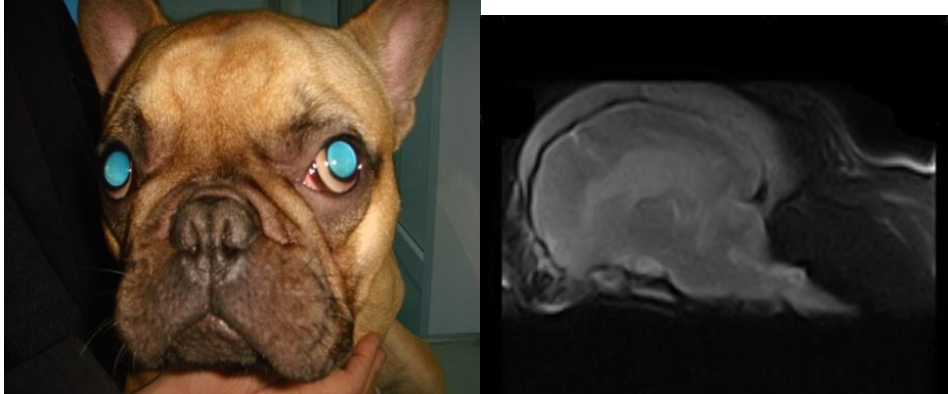

Figure 5. 1 year old dog with bilateral mydriasis, blindness, with no other neurological/ophthalmological signs. RMN: optic chiasm hemorrhages

CONCLUSIONS

Using light stimuli of different wavelength (red and blue) it is possible to easily differentiate between rod-cone mediated pupillary response (outer retina) and melanopsin-mediated pupillary response (inner retina).

CPR is a fast and easy way to separate the disorders affecting the outer retina from those affecting the inner retina. Decreased, incomplete or absent CPR to red light stimuli but normal CPR to blue light stimuli suggests a photoreceptors' damage, whereas an absent CPR to blue light stimuli suggests a melanopsin-containing retinal ganglion cells, or optic nerve damage.

The chromatic pupillary response (CPR) proved to be a “foothold” in the diagnosis of ophthalmological disorders (retinal detachment, progressive retinal atrophy) and neurological disorder (glaucoma, brain tumor, optic chiasm tumor) before complementary expensive tests were performed.

REFERENCES

- Ecker J., Dumitrescu O.N., Wong K.Y., Alam N.M., Chen S.K., LeGates T., Renna M.J., Prusky G.T., Berson, D.M., Hattar S., 2012. Melanopsin-expressing retinal ganglion-cell photoreceptors: cellular diversity and role in pattern vision. *Neuron*, 67, 49-60
- Grozdanic S.D., Matic M., Sakaguchi D.S., Kardon R.H, 2007. Evaluation of retinal status using chromatic pupil light reflex activity in healthy and diseased canine eye. *Investigative and ophthalmology visual science*, 48, 5178-5183.
- Hattar S., Liao H.W., Takao M., Berson D. M., Yau K.W., 2002. Melanopsin-containing retinal ganglion cells: architecture, projections, and intrinsic photosensitivity. *Science*, 295, 1065-1070

Kardon R., Anderson S.C., Damarjian T.S., Grace E.M., Stone E., Kawasaki A., 2009. Chromatic pupil responses: preferential activation of the melanopsin-mediated versus outer photoreceptor-mediated pupil light reflex. *Journal of the american academy of ophthalmology*, 116, 1564-1573.

Markwell E.L., Feigl B., Zele A.J., 2010. Intrinsically photosensitive melanopsin retinal ganglion cell contributions to the pupillary light reflex and circadian rhythm. *Clinical and experimental optometry*, 93, 137-149.