

THE IMPORTANCE OF INTRAOPERATIVE RETROBULBAR BLOCK ON ANESTHETIC MANAGEMENT OF ENUCLEATION

Gina-Teodora Girdan, Iuliana Ionașcu

University of Agronomic Sciences and Veterinary Medicine of Bucharest, Faculty of Veterinary Medicine, Splaiul Independenței 105, Bucharest, Romania, gina_girdan@yahoo.com

Abstract

One of the major goals of anesthesia is control the pain. For far too many years the veterinary profession has considered analgesia and pain management to be of little interest with practitioners as quoted outdated aphorisms as “ animals feel less pain than humans”, or “pain is beneficial because it limits movement”and “analgesia mask clinical degeneration ”. Now we know that all these are totally false and that pain affects life and rehabilitation of patients in a tremendous way.

The aim of this article is to clarify specific conditions that occur in anesthesia following retrobulbar block using as reference parameters : pupillary reflex and position of the eyeball, before and after the block but also the heart rate and non invasive blood pressure.

Key words: analgesia, eye enucleation, retrobulbar block.

INTRODUCTION

Pain has been defined by International Association for the Study of Pain as ”an unpleasant sensory and emotional experience associated with actual or potential tissue damage ”.

Local anesthetics are extremely useful in surgery procedures for providing analgesia and pain management, increasing the benefits in anesthesia protocol .

Retrobulbar block represents a regional anesthetic nerve block into the retrobulbar space, providing akinesia of extraocular muscles by blocking cranial nerves II, III ,IV, V (ophtalmic and maxillary branches) and VI, thereby preventing movement of the globe; it is a very useful procedure for enucleation surgeries, being an important tool for managing anesthetic

safety and patient comfort especially in old animals less tolerant of higher anesthetic levels.

MATERIALS AND METHODS

The animals that have been used for the study and proposed for enucleation were examined at Faculty of Veterinary Medicine, Department of Ophthalmology, both dogs and cats developing clinical conditions such as: glaucoma and buphtalmia (Figure 1), penetrating corneal wounds with lack of substance, descemetocoele, avulsion of the eyeball, intracameral neoplasms, uveitis and phthisis bulbi, especially encountered in viral feline rinotracheitis, etc. Contraindications for this technique were: inflammation, retrobulbar processes or abscesses.

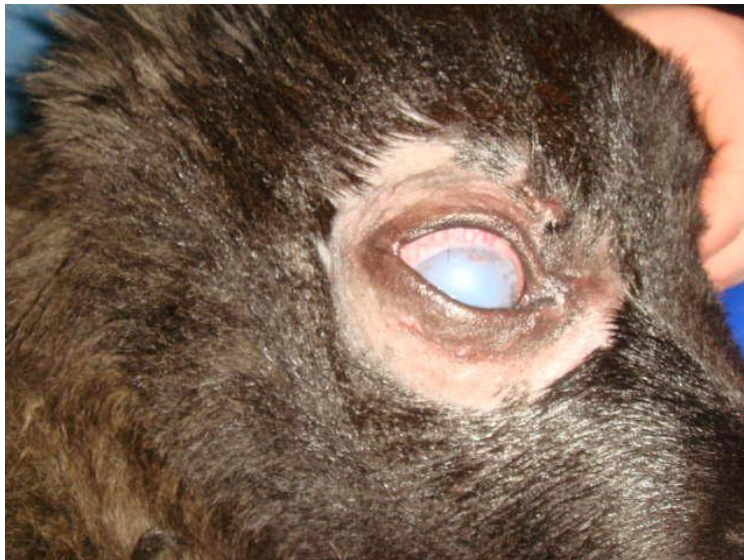

Figure 1. Buphtalmia before retrobulbar block

Retrobulbar block was performed under general anesthesia using both, total intravenous anesthesia (TIVA) or inhalatory technique. There have been used different protocols of anesthesia for TIVA protocol, according to ASA, such as: in premedication Acepromazine 10-40 $\mu\text{g}/\text{kg}$, \pm an nonsteroidal Anti-inflammatory drug (Onsior, Metacam, Rymadyl, and

Tolfedine) followed by placing a catheter for induction and maintenance using BLK cocktail (in 500 ml NaCl 0.9%, Butorphanol 10 mg, Lidocaine 120mg, and Ketamine 500 mg). Another example for TIVA protocol was premedication with Acepromazine 10-40 µg/kg, ± an nonsteroidal Anti-inflammatory drug, than for induction and maintenance using Diazepam and Ketamine iv mixture 1:1. Inhalation anesthesia was performed with Acepromazine 10-40 µg/kg and Tramadol 2-5 mg/kg, ± an nonsteroidal Anti-inflammatory drug in premedication, followed by induction with Propofol 4-6 mg/kg, and maintenance with Isoflurane 1-2%.

Local anesthetics used for the surgeries were Lidocaine 2% 2-4 mg/kg and Bupivacaine 0.5% 1-2 mg/kg, mixed into the same syringe. The doses for lidocaine was halved in cats.

Retrobulbar block in our study was performed using both inferior temporal palpebral, and superior temporal palpebral injection techniques (Figure 2); it appears to be an intimidating-looking procedure, but it is really easy and safe. There are few steps to be followed :

- Hair clipping and skin disinfection of the affected eye.

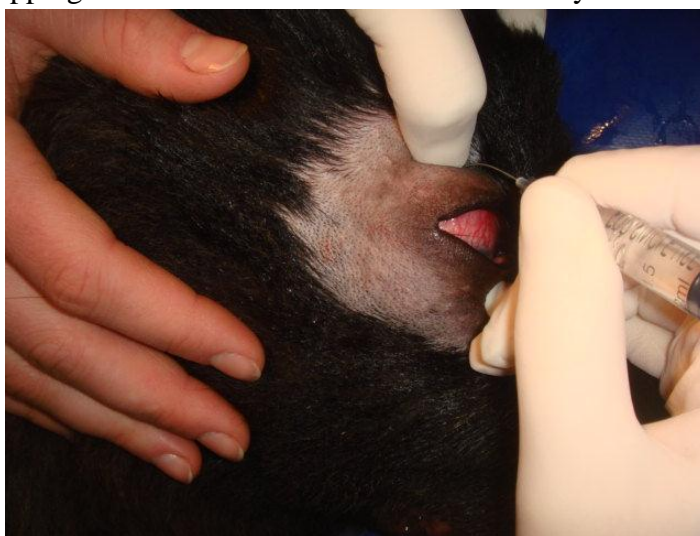

Figure 2. Retrobulbar block by palpating the superior orbital rim

- The conjunctiva is anaesthetized using topical eye anesthetics such as Benoxycaine (Figure 3).

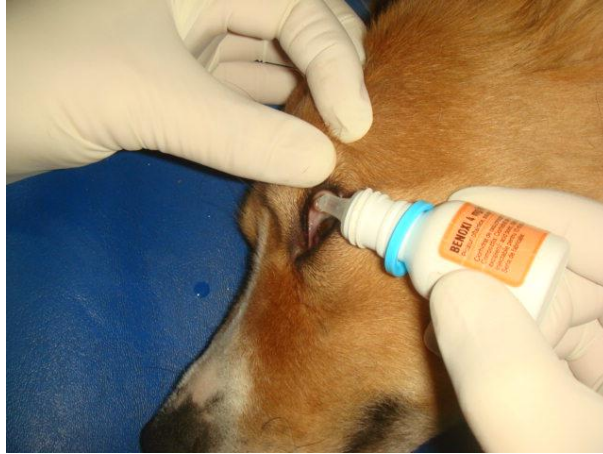

Figure 3. Topical eye anesthetics such as Benoxycaine.

- Use a 22, 23 standard needle which is slightly bent (15-degree) in its middle.
- Place the needle perpendicular to the skin, directed medially toward the retrobulbar area.
- Advance the needle in the caudomedial direction. With the slight bend in the needle, advancing it will naturally follow this course.
- Once placed, aspirate. If there is no blood into the syringe, inject the local anesthetic (Figure 4).

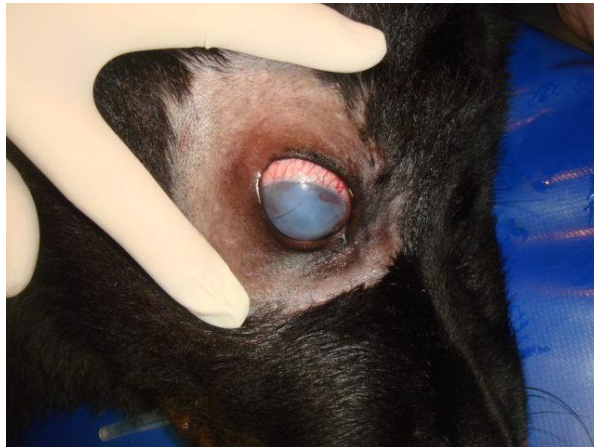


Figure 4. Exposure of the globe after retrobulbar block

- For enucleation, after closure of the lids, administer a peri-incisional infiltration of bupivacaine because the skin of the face would not have been blocked by the retrobulbar local anesthetic.

Complications associated with this block are either local or systemic. Local ocular include hematoma formation, which is the most common complication seen because of inadvertant puncture of vessels within the retrobulbar space, perforation of the globe and neuritis.

Systemic complications include oculocardiac reflex, local anesthetic toxicity and brainstem anesthesia.

Oculocardiac reflex represents a decrease in pulse rate following eye manipulation during the procedure. The reflex is mediated by nerve connections between the trigeminal cranial nerve and the vagus nerve of the parasympathetic nervous system. There were patients which developed the reflex in which heart rate suddenly dropped between 30 to 50 beats per minute. In some of them did not use anything and they successfully recovered by avoiding manipulation and for the others, there have been used atropine 0.02-0.04mg/ kg.

RESULTS AND DISCUSSIONS

Effectiveness of injection with local anesthetic (lidocaine2% and bupivacaine 0.5%) into retrobulbar space following eye enucleation has shown two aspects: first one is that provides akinesia of the extraocular muscles by blocking cranial nerves II,III and VI, thereby preventing movement of the globe and providing comfort for the surgeon's technique and the second one is that requires less anesthetic substance conferring additional analgesia and reducing the need for additional intra or postoperative analgesics.

CONCLUSIONS

Retrobulbar block acts as a part of polymodal analgesia of intraoperative anesthetic protocol for enucleation surgeries and can greatly improve our ability to provide complete and compassionate care.

Maintaining good analgesia makes practice more enjoyable for us, and definitely improves the quality of our patients' lives.

REFERENCES

- Accola P.J., Bentley E., Smith L.J., et al, 2006. Development of a retrobulbar injection technique for ocular surgery and analgesia in dogs. *Journal of the American Veterinary Medical Association*, 229(2), 220-225.
- Dugdale A., 2010. *Veterinary anaesthesia. Principles to practice.* Willey Blackwell, UK.
- Epstein M.E., 2011. Six practical loco-regional blocks you should be using. A second look at local blocks and strategies for effective administration. *Dvm Newsmagazine*
- Giuliano Elizabeth, BRAVO 2006 Regional anesthesia as an adjunct to eyelid surgery
- Johnson S.M., Saint John B.E., Dine A.P., 2008. Local anesthetics as antimicrobial agents. *Surgical Infections*, 9, 205-213.
- Myrna K.E., Bentley E., Smith L.J., 2010. Effectiveness of injection of local anesthetic into the retrobulbar space for postoperative analgesia following eye enucleation in dogs. *Journal the American Veterinary Medical Association*, 237(2):174-177.
- www.vasg.org Veterinary Anesthesia & Analgesia Support Group; Practical Advice for the Compassionate Veterinary Practitioner
- www.wikipedia.org Retrobulbar block.