

STUDIES ON HISTOLOGICAL STRUCTURES OF THE ABDOMEN ON ADULT WORKER BEES (APIS MELLIFERA CARPATHICA)

Petruț T.¹, D. Condur¹, N. Velicu¹, V. Călin¹

1 Faculty of Veterinary Medicine Spiru Haret, 9-11 Energeticienilor Blvd, 032091, Bucharest, Romania, 021.2421576, tanasepetrut@yahoo.com

Abstract

In an initial phase, the studies aimed possibilities of including chitinous anatomical segments by using different fixing solutions in order to produce chitin lysis to facilitate cutting them. Various fixing solutions have been used (glacial acetic acid, Carnoy fixative, trichloroacetic acid, picric acid, acetone, absolute alcohol, Bouin's fixative, etc.) with variable terms in determining the degree of chitin lysis, which proved to be inefficient, the parts included being improper to sectioning (cutting friability and lack of integrity in tissue resulting from staining). In a later stage, they proceeded to a careful dissection, under the microscope, of the anatomical organs of the abdominal cavity in order to dissociate the anatomical segments present at this level to prepare it for inclusion. Processing of samples was also performed under the microscope until their inclusion in paraffin.

Detailed histological examination of tissue and cellular structures, captures the structural aspects at a time. The serial sections revealed the histological structure of several organs located in the abdominal cavity. This positioning of organs in sections led to their identification, facilitating their microscopic interpretation.

Key words: worker bees, abdominal cavity, histological structures.

INTRODUCTION

Bees are very little known at the microscopic and molecular level, despite the fact that long have been subject to studies of social behavior (Winston, 1991).

The first data on bee anatomy has a considerable experience, one of the works on this topic being the drawing of the Italian microscopist Francesco Stella. It was the bee's anatomy as was revealed under the microscope, sketch published in 1625 (Bazin et al., 1976).

Later, with the development of the microscopic techniques the knowledge about the insects and about the bees were also improved, with the disadvantages related to the chitinous exoskeleton, preventing proper sectioning insects embedded in paraffin (Graham, J. M., 1992).

Lately they started electron microscopy examination of the various structures, with a higher resolution (Dade, 1977). They brought major

improvements such as knowledge of anatomy and physiology of bees (Goodman, 2003).

MATERIALS AND METHODS

The samples collected were fixed in formol saline, were then prepared for inclusion in paraffin and then sectioned in series in order to capture the histological structure of organs in the abdominal cavity.

By histological examination after sampling, fixed in neutral formalin saline and further processed for inclusion in paraffin. Paraffin blocks were sectioned at 6 μm , stained preparations were obtained by HE and the trichromic method of Mallory, examined and microphotographed.

RESULTS AND DISCUSSION

The serial sections revealed the histological structure of several organs located in the abdominal cavity. This positioning of organs in sections led to their identification, facilitating their microscopic interpretation.

Venom glands (venom sac) appear obvious, bulky-looking tube. Gland lumen cross-sectional appear anfractuos and filled with secretions.

Microscopic structure of this type of gland cross-sectioned reveals the presence of two histostructural components (fig. 1):

- the epithelial component with secretory role;
- muscle component.

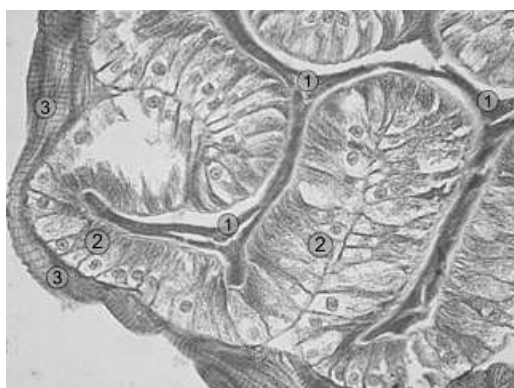

Fig. 1 - Venom gland (cross section);
Col. HE; Ob. 40x
1. lumen of gland; 2. epithelial layer;
3. muscular layer.

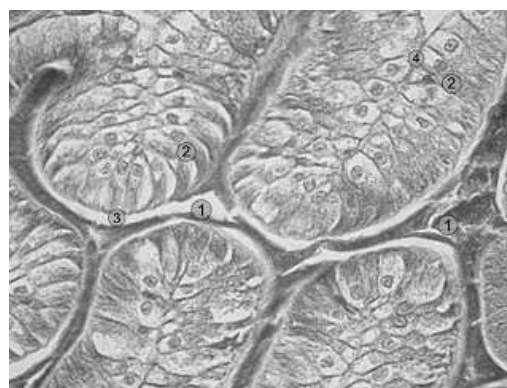

Fig. 2 - Venom gland (cross section);
Col. HE; Ob. 100x
1. lumen of gland; 2. prismatic cells;
3. apical pole; 4. basal pole.

The epithelial component consists of simple columnar epithelium (prismatic) located on an evident basement membrane. The secretory epithelial cells have prismatic appearance, showing a high pole located on the basal membrane and an apical pole filled with secretory vacuoles. The nucleus is spherical and located in the lower third of the cell showing a clear nucleolus. The overall secretory cells form numerous folds in the glandular lumen that gives an anfractuos appearance (fig. 2).

The ovary is presented as a devolved body, consisting of capsule conjunctiva located on the periphery of the organ and internally organized as individual mass of germ cells. Between germ cells and capsule a perigerminative space is defined (fig. 3).

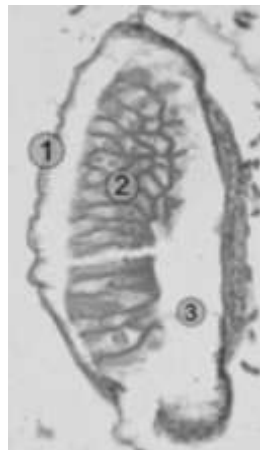

Fig. 3 - Ovary; Col. HE; Ob. 20x
1. cuticle; 2. germ cells; 3. perigerminative space.

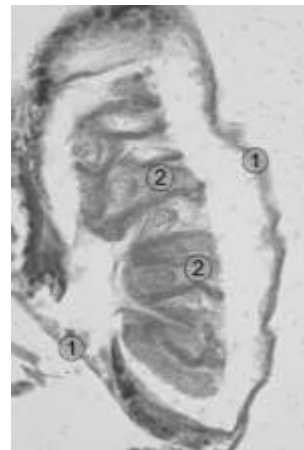


Fig. 4 - Ovary; Col. HE; Ob. 40x
1 - cuticle; 2 - germ cells.

Detailed examination (Ob. 40x) shows an evident capsule consisting of collagen fibers arranged in beams, arranged concentrically around the atrophied ovary (fig. 4).

Cubic form germ cells with a spherical nucleus centrally located in the mass of germ cells appear surrounded by stroma separating ovarioles between them.

The goiter (honey stomach) is a big hollow section, which presents particular external peripheral muscle structure composed of muscle fibers arranged in two concentric layers of longitudinal and transverse layout.

To internal lumen epithelial cells are disposed at different heights showing apical plasmalemma changes in appearance of cytoplasmic veils (fig. 5).

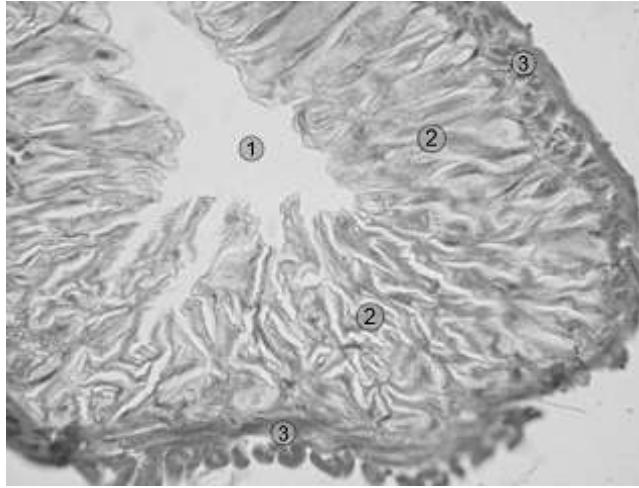


Fig. 5 - Honey stomach; Col. Mallory trichromic; Ob. 40x
1. lumen; 2. epithelial cells, 3. muscular layer.

High waist epithelial cells have a nucleus with an obvious nucleolus, not so intense in activity in terms of protein synthesis, with role in secreting some products needed for honey maturation produced for regurgitation. Sounds like a storage tank and processing honey to be removed later by the concerted action of the muscle layer, highly developed than other hollow organs.

The intestine has a totally different histological architecture than honey stomach. The epithelium is evident with higher cellularity compared to honey stomach, while the peripheral muscular structure is much finer (fig. 6).

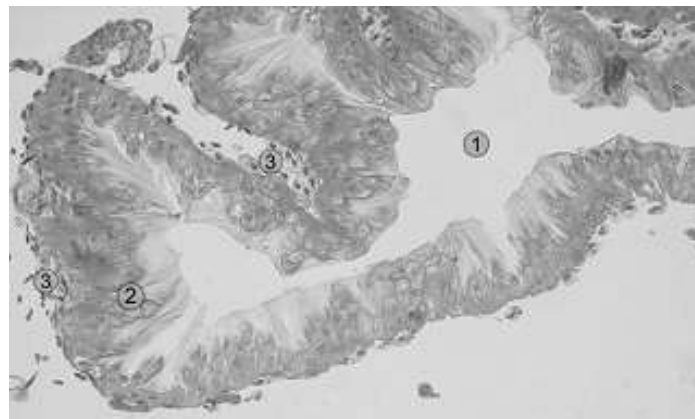


Fig. 6 - Intestine (longitudinal section); Col. Mallory trichromic; Ob. 10x
1. lumen; 2. epithelial cells, 3. muscular layer.

Detailed examination (Ob. 20x; 40x) observed similar characteristics to honey stomach cells in terms of changes in the apical pole plasma; the exquisite muscle layer consists of an orderly succession of muscle fibers arranged longitudinally (fig. 7).

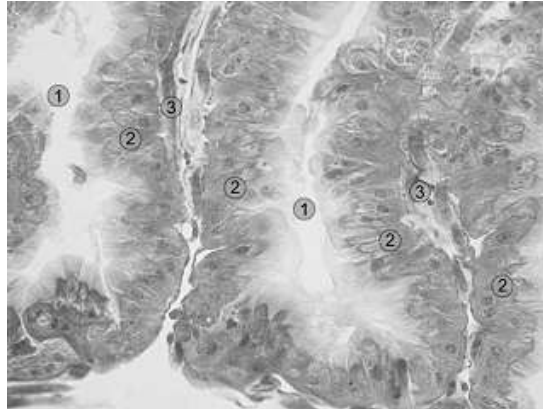


Fig. 7 - Intestine (longitudinal section); Col. Mallory trichromic; Ob. 20x
1. lumen; 2. epithelial cells, 3. muscular layer.

Highlighting arrangement and intercellular relationships in the epithelium is shown by fig. 8 in which intestinal cells have a uniform arrangement on the basal membrane. It can be said that there are basal cells (with regenerative role) and proper intestinal cells. Plasma changes appear obvious on the apical pole and also an intensely colored area which may be similar to „corrugated plate” with a role of increasing power reabsorption at this level.

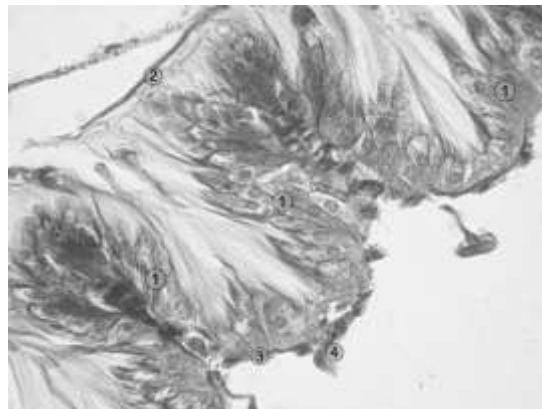


Fig. 8 - Intestine (longitudinal section); Col. Mallory trichromic; Ob. 40x
1 - intestinal cells, 2 - apical pole, 3 - basal pole, 4 - muscle cells.

CONCLUSIONS

Histostructural characterization and early identification of abdominal hollow organs, in conjunction with topographic arrangement have been made.

These organs are the main sections in correlation with hemo-lymphatic compartment, responsible, probably in the process of activation of humoral and cellular immune mechanisms in the haemolymph.

In the future it is intended to increase the accuracy of the characterization and identification of abdominal organs in working bee by enzymatic and histochemical research.

As will be identifying histological bodies will be able to make correlations with various pathological conditions (deficiency, parasitic, bacterial, etc) present in bee populations and relevant in terms of histopathological examination.

REFERENCES

- Bazin, B., KümmeL, G., Zerbst, Boroffka, 1976, Studies on the rectal pads of the honey bee *Apis mellifera*, *Naturforsch*, 31 (7-8), pp. 489-490.
- Dade, H.A., 1977, Anatomy and dissection of the honey bee, International Bee Research Association, London, pp. 158.
- Goodman, L.J., 2003, Form and function in the honey bee, International Bee Research Association, Cardiff, pp. 220.
- Graham, J. M., 1992, *The Hive and the Honey Bee*, Revised Ed. Dadant & Sons, Hamilton Illinois, U.S.A.
- Winston, Mark, L., 1991, *The biology of the honey bee*, First Harvard University Press paperback edition, pp. 13-45; pp. 181-198.