

OCCURRENCE OF PARASITIC AND *Malassezia* OTITIS EXTERNA IN DOGS AND CATS: A RETROSPECTIVE STUDY IN A PRIVATE PRACTICE IN SOUTHERN ROMANIA

George Andrei NECULA, Mariana IONITA, Ioan Liviu MITREA

University of Agronomic Sciences and Veterinary Medicine of Bucharest, Faculty of Veterinary Medicine, Spl. Independentei, 105, Bucharest, Romania

Corresponding author email: andrei.necula92@yahoo.com

Abstract

Parasites and fungi cause otitis externa in dogs and cats and have an important impact on the welfare of the affected animals. Moreover, their control is often problematic. Here we present a retrospective study on the occurrence of otitis externa in client owned dogs (n=179) and cats (n=157) that were presented in a veterinary practice during a one-year period. All animals were subjected to the routine clinical examination followed by direct otoscopy and microscopic evaluation of ear exudates with and without Diff-quick staining. Of the investigated dogs and cats, 16.75% and 19.75%, respectively were diagnosed with otitis externa. Of the dogs, 10.05% (18/179) were positive for mixed *Malassezia* and *Otodectes* infestations, 5.58% (10/179) only with *Malassezia*, and 1.11% (2/179) with only *Otodectes*. In cats, 8.28% (13/157) of the animals were diagnosed with *Malassezia* and *Otodectes* mixed infestations, 11.46% (18/157) of cats had only *Malassezia* otitis, and none had only parasitic infestation. Overall, of the 30 dogs and 31 cats diagnosed with otitis externa, 43.33% and 32.25%, respectively, were presented for ear related problems. In conclusion, these findings showed a positive correlation between *Malassezia* and *Otodectes* otitis in dogs, while in cats *Malassezia* otitis externa was detected in all parasitic infestations of the ear. Additionally, the study underlines the importance of ear examination and microscopic evaluation for a proper therapeutic protocol.

Key words: otitis externa, dogs, cats, Southern Romania.

INTRODUCTION

Otitis externa is an inflammation of the external ear canal distal to the tympanic membrane; the ear pinna may or may not be involved (August, 1988). It is one of the most common reasons for small animals (especially dogs) to be presented to the veterinarian (Bruyette & Lorenz, 1993; Jacobson, 2002). Otitis externa can exhibit an acute or chronic evolution and can be unilateral or bilateral clinical condition. As response to chronic inflammation, changes that occur in the external ear canal may include different pathologies, such as glandular hyperplasia and/or dilation, epithelial hyperplasia, and hyperkeratosis (Huang & McNeil, 2009; Njaa & Tabacca, 2012).

Malassezia yeast is a common causative agent of otitis externa in dogs (Weisbroth et al., 1974; Murphy, 2001). Moreover, it is reported that some dogs appear to develop an allergic response to *Malassezia* spp., which leads to

significant pruritus and discomfort (Mitrea, 2011; Bajwa, 2019; Brame, & Cain, 2021).

Several parasites have been associated with otitis externa, especially *Otodectes* but also *Demodex* and *Sarcoptes* (Powell et al, 1980). Among them, the ear mite *Otodectes cynotis* is quite common, being reported in the past for up to 50% of the otitis externa cases diagnosed in cats and 5% to 10% of the cases in dogs (August, 1988; Karen, 2022).

Ear mites may initiate otitis externa but remain undetected. One reason is the difficulty that may occur in demonstrating the mites. As few as two or three mites can cause otitis externa (Murphy, 2001; Jacobson, 2002; Karen, 2018). This has been explained by studies showing that ear mites can induce Arthus-type and immediate-type hyper-sensitivity reactions (Rosychuk, 1994; Brame & Cain, 2022). Another explanation is that the mites initiate the otitis externa and then leave the canal or are eliminated by secondary induced inflammation (Bruyette & Lorenz, 1993; Logas & Maxwell, 2021).

Causes of otitis externa could be primary or secondary, with a variety of predisposing and perpetuating factors that contribute to/or promote the disease. Collectively, these causes and factors are referred to as the primary secondary predisposing perpetuating (PSPP) classification system (Bruyette & Lorenz, 1993; Jacobson, 2002; Karen, 2022).

Primary causes of otitis externa create disease in a normal ear. They alter the environment in the ear, often allowing a secondary infection to develop. Primary causes include: allergy (adverse food reaction, atopic and contact dermatitis), parasites (*Otodectes*, *Demodex*, *Sarcoptes*), autoimmune/immune-mediated (pemphigus foliaceus, vasculitis, others) endocrine disease (hypothyroidism, hyperadrenocorticism), epithelialization disorders (sebaceous adenitis, zinc-responsive dermatitis), foreign bodies glandular disorders (sebaceous gland hyperplasia), fungal (*Aspergillus*) viral (distemper), miscellaneous (proliferative necrotizing otitis of cats, juvenile cellulitis) (Powell et al., 1980; Brame & Cain, 2021).

Secondary causes of otitis externa create disease in an abnormal ear. These are often chronic/recurrent problems when the primary cause is not addressed. Secondary causes include bacteria (*Staphylococcus*, *Streptococcus*, *Enterococcus*, *Pseudomonas*, *Proteus*, etc), yeast (*Malassezia*) medication reactions, overcleaning (August, 1988; Rosychuk, 1994; Zaman et al., 2010; Brame & Cain, 2021; Logas & Maxwell, 2021).

Perpetuating factors occur due to otic inflammation and may be severe in chronic cases. They include changes of the epithelium (failure or alteration of migration; migration of the epithelium of the ear canal provides a natural cleaning mechanism in normal ears) of the ear canal (stenosis, oedema, proliferative changes), of the tympanum (rupture), of the glandular tissue (sebaceous hyperplasia), as well as pericartilaginous fibrosis or calcification middle ear disease (Powell et al., 1980; Zaman et al., 2010).

Predisposing factors increase the risk for developing otitis externa. These include: conformation (pendulous pinna, stenotic canals, hairy concave pinna, excessive hair in canals), excessive moisture (environment, swimming), obstructive ear disease (neoplasia,

polyp, feline apocrine cystadenomatosis), primary otitis media, systemic disease (immune suppression, catabolic states), treatment effects (changes in normal flora, trauma) (Powell et al., 1980; Jacobson, 2002; Bajwa, 2019).

Malassezia spp. infections are a common secondary cause of otitis or inflammation of the ear canal (Mitreá, 2011). It is a yeast that normally lives in the ears of cats and dogs but overgrows when the environment of the ear canal changes. This change is a result of increased fatty secretions and moisture, making it easier for the *Malassezia* to multiply. Some primary, or underlying, causes of ear infection include allergies (atopic dermatitis or food hypersensitivity) and narrowed ear canals. Studies have shown that bacteria can be found in combination with a *Malassezia* otitis (Jacobson, 2002; Bajwa, 2019; Logas & Maxwell, 2021).

Otitis externa is a multifactorial disease with a complicated management that severely impacts animal wellbeing (August, 1988). In small animal practices it can be one of the most frustrating diseases to manage. Understanding how primary and secondary factors intervene in the pathogenesis of this disease is key to increasing the success rate of treatment (Rosychuk, 1994).

Therefore, the purpose of this study was to evaluate the occurrence of yeast and parasitic otitis in dogs and cats, and to better understand the correlation between them, as a documented base of treatment and better control the disease.

MATERIALS AND METHODS

Clinical examination and sampling

A number of 179 dogs and 157 cats were enrolled in this study during a 1-year period. During this time, a total of 457 animals (241 cats and 216 dogs) were referred to the clinic. The examined animals were kept both outdoor and indoor, and were admitted to the clinic for various reasons, most common being vaccinations and yearly check-ups but also for otic pruritus, head rubbing, headshaking and other ear related symptoms.

For all animals a thorough clinical examination of the ear pinnae canals was carried out using an otoscope whenever possible.

Samples of cerumen and discharges were collected from both ears for further microscopic ear mite detection, as well as for modified Wright Giemsa staining for detection of *Malassezia* yeasts.

Laboratory examination

For ear mite detection, from the collected cerumen and otic discharge smears were prepared with the addition of a small quantity of mineral oil on a microscopic glass slide (Ionita & Mitrea, 2013). A clean glass coverslip was put on the top surface of the smear and examined microscopically (40x and 100x obj.) on the same day, for the presence of adult mites, nymphs, larvae, or eggs (Figure 1).

For Malassezia yeast detection, smears were performed from collected cerumen and otic discharge, and were modified Wright Giemsa (Diff-Quick) stained. After staining, the smears were examined using a 100x oil objective (Figure 2).

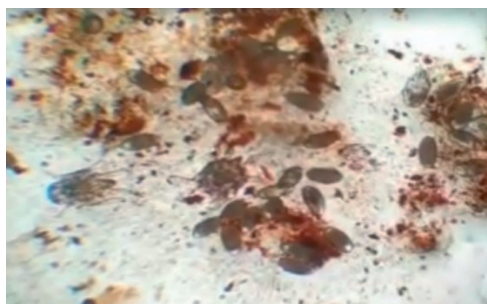


Figure 1. *Otodectes cynotis* infestation – adults, eggs – in a cerumen smear of a cat (original)

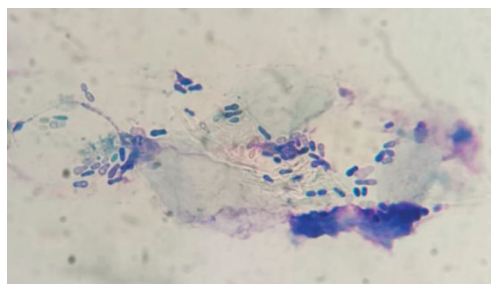


Figure 2. *Malassezia* yeast infection found in a cat with external otitis (original)

RESULTS AND DISCUSSIONS

A total number of 179 dogs (88 males, 91 females), of different breeds and age varying

from 1 month to 10 years (average: 24 months; Standard Deviation [SD]: 29.17), with clinical signs (n=17; 9.49%) and without signs of external otitis, were examined.

Of the investigated dogs, 30 (16.75%) were diagnosed with external otitis after clinical examination. Their age varied from 2 to 10 years (mean age of 29.73 months; SD: 30.45). The laboratory examination revealed that out of the 30 dogs diagnosed with otitis, 2 animals were positive for single *Otodectes cynotis* infestation, 10 animals positive for single *Malassezia* yeast infection and 18 with mixed *Otodectes* and *Malassezia* infestations (Table 1).

Overall, the prevalence of *Malassezia* spp. was 15.6% (n=28) and for *O. cynotis*, 11.2% (n=20). Single infections with either *Malassezia* or *Otodectes* were present in 6.7% (n=12) of dogs whereas mixed infections were present in 10.05% (n=18) of dogs (Table 1, Figures 3 and 4).

Table 1. Distribution of causal agents in dogs and cats with external otitis

Animal Species	Total Cases	Single infection		Mixed infection
		<i>Malassezia</i> spp.	<i>Otodectes cynotis</i>	
Dog	30	10	2	18
Cat	31	18	0	13

With regards to cats, a total number of 157 cats (79 males, 78 females) of different breeds and age varying from 3 to 13 years old (average: 25 months; SD \pm 29.7) with signs (n=25; 15.92%) and without signs of external otitis. Of these, a number of 31 (19.75%) were diagnosed with external otitis after clinical examination. Their age varied from 3 months to 13 years (mean age of 32.3; SD: 17.54 months).

The laboratory examination revealed that among the cats diagnosed with otitis, 18 animals were positive for *Malassezia* infestation and 13 with mixed *Malassezia* and *Otodectes* infestations. None of the examined cats was infected only *Otodectes* (Table 1).

Overall, in the investigated cats, the prevalence of *Malassezia* was 19.75% (n=31), and of *Otodectes* 8.3% (n=13).

Single *Malassezia* infections were present in 11.5% (n=18) of cats.

There were no single *Otodectes* infections in the examined cats (Figures 3 and 4).

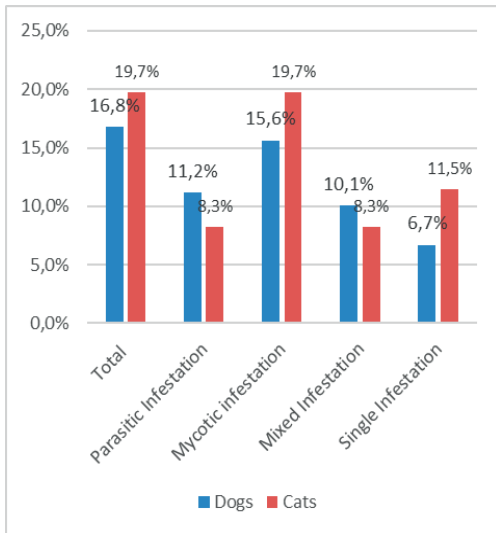


Figure 1 Comparative prevalence of pathogens in dogs and cats with external otitis

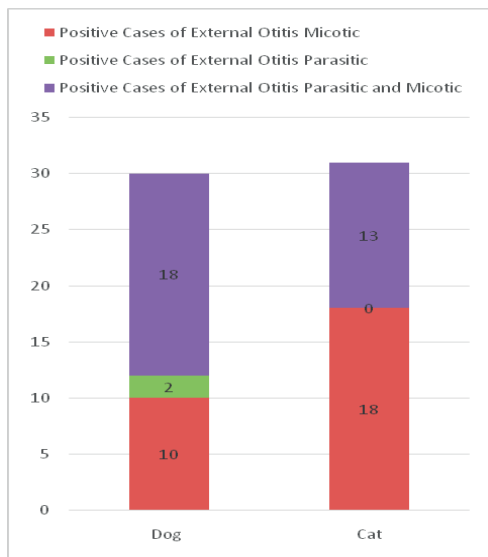


Figure 2. Distribution of the causative agent in positive dogs and cats for external otitis

DISCUSSIONS

This retrospective study that investigates the occurrence of otitis externa in client-owned dogs and cats emphasizes that 16.75% of the examined dogs and 19.75% of the cats were diagnosed with otitis externa.

Moreover, of the positive animals, only 43.33% of the dogs and 32.25% of the cats were brought by the owners for ear clinical signs.

Therefore, these findings highlight the need for thorough evaluation of the ear for every animal presented for a consultation.

Evaluation of cerumen and otic discharge with and without staining alongside otoscopic evaluation are important for correctly identifying the underlying disease.

Also, the result showed a positive correlation between parasitological infections of the ear and the presence of *Malassezia* yeast infections in both dog and cat.

In cats it was observed that *Malassezia* yeast infection accompanies all *Otodectes* infections.

As reported, animals with external otitis are not always presented by the owner due to specific clinical signs. In this study, the owners recognized ear-related clinical signs in 43.33% of the positive dogs and 32.25% of the positive cats, suggesting that owners are likely to overlook some ear problems (fig. 5).

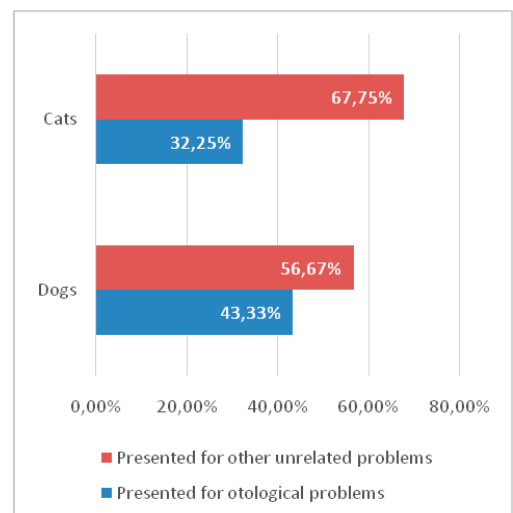


Figure 3. Percentage of animals that were presented to the clinic for otological problems

Additionally, it is worthy of mentioning that apart from mycotic and parasitic, many bacteria can accompany an external otitis. According to others studies, the most isolated bacteria from the ear canals of dogs affected by otitis is *Staphylococcus* spp (Bruyette, 1993). Other bacteria commonly associated with otitis include *Pseudomonas*, *Proteus*, *Enterococcus*, *Streptococcus*, and *Corynebacterium*. Some bacteria such as *Staphylococcus* and *Pseudomonas* may produce biofilm, which can

lead to persistence of infection despite adequate therapy, as the biofilm needs to be disrupted for any antimicrobial therapy to be effective in clearing the infection.

It is well known that otitis externa is an important pathology in dogs and cats and in most cases is caused by multiple factors. Given this fact, it is important to use microscopic evaluation in all animals with ear problems for determining the optimal therapeutic protocol. Therefore, an integrated approach, based on clinical, biological and medical features will assure a successful parasitological control (Mitrea, 2002).

CONCLUSIONS

The findings of the present study describe occurrence of parasitic and *Malassezia* otitis externa in dogs and cats, and show a positive correlation between *Malassezia* and *Otodectes* otitis in dogs, while in cats *Malassezia* otitis externa was detected in all parasitic infestations of the ear. Furthermore, the study underlines the importance of ear examination and microscopic evaluation for a proper therapeutic protocol.

REFERENCES

- August, J.R. (1988). Otitis externa. A disease of multifactorial etiology. *The Veterinary Clinics of North America. Small Animal Practice*, 18(4), 731–742. [https://doi.org/10.1016/S0195-5616\(88\)50076-1](https://doi.org/10.1016/S0195-5616(88)50076-1).
- Bajwa, J. (2019). Canine otitis externa - Treatment and complications. *The Canadian veterinary journal = La revue veterinaire canadienne*, 60(1), 97–99.
- Brame, B., & Cain, C. (2021). Chronic Otitis in Cats: Clinical management of primary, predisposing and perpetuating factors. *Journal of feline medicine and surgery*, 23(5), 433–446. <https://doi.org/10.1177/1098612X211007072>.
- Bruyette, D. S., & Lorenz, M. D. (1993). Otitis externa and otitis media: diagnostic and medical aspects. *Seminars in veterinary medicine and surgery (small animal)*, 8(1), 3–9.
- Huang, H. P., Little, C. J., & McNeil, P. E. (2009). Histological changes in the external ear canal of dogs with otitis externa. *Veterinary dermatology*, 20(5-6), 422–428. <https://doi.org/10.1111/j.1365-3164.2009.00853.x>.
- Ionita, M, Mitrea, I.L. (2013). *Diagnosticul parazitologic al animale*. Ghid de laborator, vol. I. Editura Ceres, Bucuresti.
- Jacobson L.S. (2002), Diagnosis and medical treatment of otitis externa in the dog and cat. *S. Afr. Vet. Ver.* 2002; 73:162–170. (Moriello K. Overview of otitis externa. Ear disorders. In MERCK veterinary manual. 2013. [April 2020].
- Karen A. Moriello, Otitis Media, and Interna in Cats Reviewed Jul 2018 | Modified Oct 2022 Retrieved from <https://www.merckvetmanual.com/cat-owners/ear-disorders-of-cats/otitis-media-and-interna-in-cats>.
- Logas, D., & Maxwell, E. A. (2021). Collaborative Care Improves Treatment Outcomes for Dogs with Chronic Otitis Externa: A Collaborative Care Coalition Study. *Journal of the American Animal Hospital Association*, 57(5), 212–216. <https://doi.org/10.5326/JAAHA-MS-7167>.
- Mitrea, I. L. (2002). Controlul parazitologic, concept biologic, medical si economic. *Revista Scientia Parazitologica* 3 (1), 79-89.
- Mitrea, I. L. (2011). *Parazitologie si boli parazitare*, Editura Ceres, Bucuresti.
- Murphy, K. M. (2001). A review of techniques for the investigation of otitis externa and otitis media. *Clinical Techniques in Small Animal Practice*, 16(4), 236–241. <https://doi.org/10.1053/SVMS.2001.27601>.
- Njaa, B. L., Cole, L. K., & Tabacca, N. (2012). Practical Otic Anatomy and Physiology of the Dog and Cat. *Veterinary Clinics of North America - Small Animal Practice*, 42(6), 1109–1126. <https://doi.org/10.1016/j.cvsm.2012.08.011>.
- Powell, M. B., Weisbroth, S. H., Roth, L., & Wilhelmson, C. (1980). Reaginic hypersensitivity in *Otodectes cynotis* infestation of cats and mode of mite feeding. *American journal of veterinary research*, 41(6), 877–882.
- Rosychuk, R. A. (1994). Management of otitis externa. *The Veterinary clinics of North America. Small animal practice*, 24(5), 921–952. [https://doi.org/10.1016/s0195-5616\(94\)50109-8](https://doi.org/10.1016/s0195-5616(94)50109-8).
- Weisbroth, S. H., Powell, M. B., Roth, L., & Scher, S. (1974). Immunopathology of naturally occurring otodectic otoacariasis in the domestic cat. *Journal of the American Veterinary Medical Association*, 165(12), 1088–1093.
- Zaman, khan Malayeri, H., Jamshidi, S., & Zahraei Salehi, T. (2010). Identification and antimicrobial susceptibility patterns of bacteria causing otitis externa in dogs. *Veterinary research communications*, 34(5), 435–444. <https://doi.org/10.1007/s11259-010-9417-y>.