

BIODIVERSITY OF THE THORACIC LIMB SKELETON IN COYPU

Anca ȘEICARU

University of Agronomic Sciences and Veterinary Medicine of Bucharest,
Faculty of Veterinary Medicine, 105, Spaiul Independenței, District 5, Bucharest, Romania

Corresponding author email: ancaseicaru@gmail.com

Abstract

The paper presents the thoracic limb skeleton of the coypu as compared to the rabbit. The scapular girdle is represented by the scapula and the clavicle, bones that are well developed in this species. The acromion is short and tuberos. The ratio between the infraspinous and supraspinous fossae is 2/1. The deltoid tuberosity of the humerus appears evident. Contrary to existing literature, which describes the absence of the supratrochlear foramen, we identified it in two of the three investigated corpses. Between the bones of the forearm a wide interosseous space is present. The thoracic basipodium is represented by 9 carpien bones because a central bone is interposed between the proximal row and the distal row. The following bones appear in the latero-medial line of the proximal row: pisiform, scaphoid, triquetral, lunate. The latero-medial line of the distal row contains the following bones: hamate, capitata, trapezoid and trapezium.

Key words: coypu, rabbit, thoracic limb skeleton.

INTRODUCTION

The coypu belongs to the *Animalia* Kingdom, *Vertebrata* Phylum, *Mammalia* Class, *Myocastoridae* Family, *coypus* Species.

This study aims to bring an addition to the existing data in the literature. The coypu, which is a semi-aquatic mammal, is used for its fur, but also for human consumption (Hrițcu et al., 2000).

The rabbit belongs to the *Animalia* Kingdom, *Vertebrata* Phylum, *Mammalia* Class, *Lagomorpha* Order, *Leporidae* Family (Coțofan et al., 1982; Harcourt-Brown, 2002) It is also used for its fur and for consumption (Coțofan et al., 1982).

The morpho-topographic knowledge of the bones of the anterior limb enables the veterinarian to properly identify the species (Coțofan et al., 2003; Brewé et al., 1994; Gheție et al., 1971).

MATERIALS AND METHODS

The study material was represented by three adult coypu and three rabbits corpses. The working methods were:

- Maceration of the limbs in water at room temperature, in order to remove the soft structures (muscles);

- Boiling, as an alternative method of processing, was performed in water with common detergents.

At the end of the maceration process, the bones were washed with water jet and subjected to the bleaching process with 11% hydrogen peroxide solution; after bleaching the bones were washed and dried.

For the removal of decomposed organic substances during maceration, direct cleaning with the scalpel, scissors and forceps were used.

After completion of the bone cleansing process, the anatomical features were described in detail, with the bones being photographed.

The homologation of the formations was made according to *Nomina Anatomica Veterinaria* 2017.

RESULTS AND DISCUSSIONS

In **coypu**, the scapular girdle includes the scapula and the clavicle that are well developed. The extremities of the clavicle merge with the sternum through a fibrous structure.

The scapula is very wide, has a transverse orientation, and an acromion with a recurved extremity.

The para-acromion is short and tuberos (Figure 1).

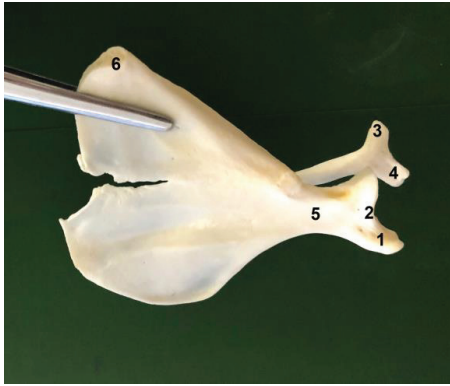


Figure 1. Scapula of the coypu - medial view (original):

- 1 - supraglenoid tuberosity; 2 - glenoid cavity;
- 3 - paraacromion; 4 - acromion; 5 - neck of scapula;
- 6 - thoracic angle

The ratio of the supraspinous and infraspinous fossae is 2: 1. The medial face of the subscapular fossa is shallow, showing muscle insertion lines. The cervical angle of the scapula is obtuse, and the thoracic angle is slightly elongated.

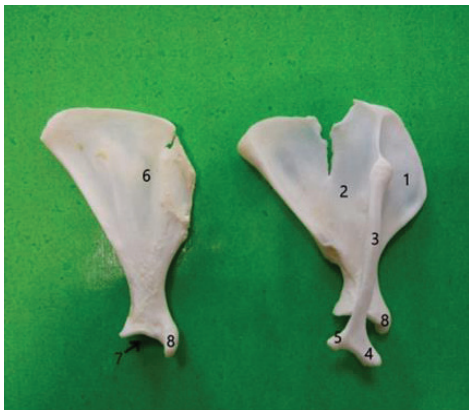

Figure 2. Scapula of the coypu - medial view (left) and front view (right) (original):

- 1 - subscapular fossa; 2 - supraspinous fossa;
- 3 - infraspinous fossa; 4 - scapular spine;
- 5 - glenoid cavity; 6 - supraglenoid tuberosity; 7 - paraacromion; 8 - acromion

The great axis of the glenoid cavity is oval with sagittal orientation. On the dorsal edge of the scapula there is a suprascapular cartilage. The cervical edge appears convex-concave, and the caudal edge is thick with numerous muscle insertion lines (Figure 2).

The humerus has a prismatic body, and the articular head exceeds in height the non-divided humeral tuberosity. Its deltoid tuberosity is well developed (Figure 3).

The humerus groove is wide, deep, while the extensor crest is evident. The tubercle for the ters major muscle is elongated dorso-ventrally.

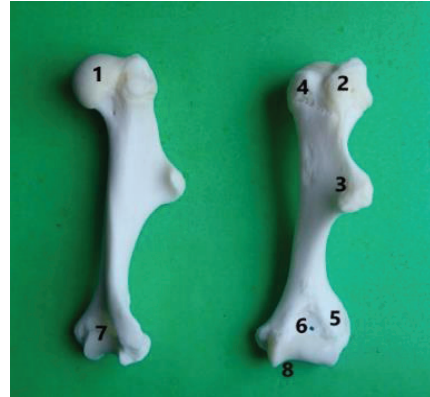


Figure 3. Humerus in coypu (original):

- 1 - humeral head; 2 - olecranian fossa; 3 - small tubercle;
- 4 - large tubercle; 5 - deltoid tuberosity;
- 6 - the lateral epicondyle crest; 7 - supratrochlear foramen;
- 8 - humeral trochlea

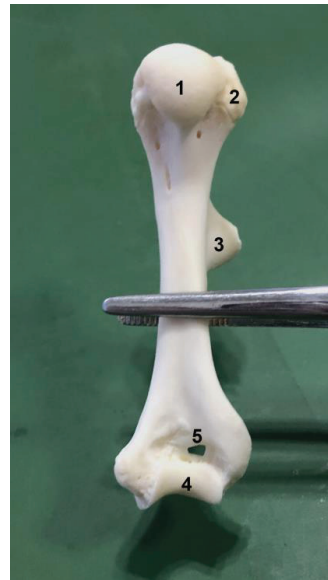


Figure 4. Humerus in coypu- cranial view (original):

- 1-humeral head; 2-small tubercle; 3-deltoid tuberosity;
- 4-distal humeral joint; 5-supratrochlear foramen

The distal humeral joint is formed by a trochlea, and the olecranon fossa has the axis disposed transversally (Figure 4). In two out of the total of three investigated corpses, the supratrochlear foramen was present, though reduced in size, while the absence of the epitrochlear foramen was noticed, contrary to the literature, which claims the absence of the both.

The radius presents well-developed medial and lateral tuberosities. The proximal extremity of the radius presents a medial-laterally elongated glenoid cavity. The body of this bone is strongly twisted in the shape of the "S" letter.

The distal extremity of the radius in coypu displays a deep and slightly wavy glenoid cavity. The ulna presents a well developed olecranon with a non incised tuberosity (Figure 5).

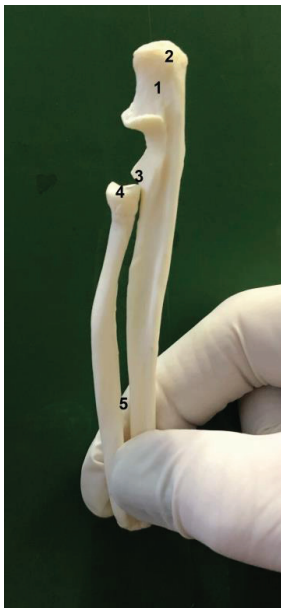

Figure 5. Radius and ulna in coypu - lateral view (original):

- 1 - olecranon; 2 - olecranon tuberosity; 3 - cranial articulation surface; 4 - articular cavity;
- 5 - interosseous space of the forearm

The semilunar incision is well outlined and very deep in its middle third. The body of the ulna is more developed than that of the radius; this particularity is different as compared to the rabbit.

Between the forearm bones in coypu there is a large interosseous space.

On the edge of the proximal extremity of the ulna there is a radial incisura which serves for the articulation of the radius (Figure 6).

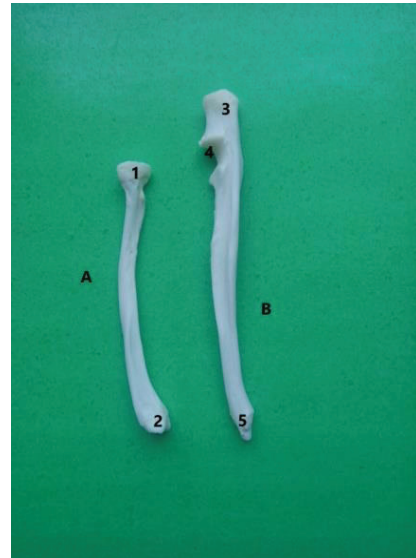


Figure 6. Zeugopodium of the anterior limb in coypu (original):

- 1 - proximal extremity of radius; 2 - distal extremity of radius; 3 - olecranon; 4 - semilunar notch; 5 - distal extremity of ulna; A - radius; B - ulna

The carpal bones in the proximal row are represented by the pisiform, pyramidal, scafo-ulnar and facoid bones. The distal row is formed by the unciform, capitate, trapezoidal and trapezium bones. Between the two rows of carpal bones there is the central bone.

The pyramidal bone has a glenoid cavity, and the scafo-ulnar bone has a glenoid cavity and a condylum. The distal extremity of the first row of carpal bones has the aspect of a flat-condyloid joint surface. The articular surface of the distal extremity from the bones in the second row, presents three glenoid cavities: one cavity for the articulation with the proximal extremity of the fourth metacarpal, a second one for proximal extremity of the third metacarpal, and the third is common for the metacarpals of fingers II and III. In coypu there are 5 metacarpal bones with a dorso-palmar flattened shape. The first finger presents a proximal phalanx and a distal phalanx. The rest of the fingers (II, III, IV, V) are made up of three phalanx. The distal phalanx presents

a prismatic form, with a flexor tubercle on the ventral face, flanked axially and abaxially by a wide and deep intertubercular groove.

Rabbits, as compared to nutria, show a series of particularities due to the specific use of the thoracic limbs. The scapula appears triangular and elongated dorso-ventrally. On its lateral side, the scapular spine ends with a long acromion and a well-developed para-acromion, as opposed to the coypu where this structure was smaller.

The ratio between the infraspinous fossa and the supraspinous fossa is 2/1. The cranial edge of the scapula is thin, with a convex dorsal half and a scapular notch on its ventral half (Figure 7). Dorsally to the glenoid cavity, there is a well-developed supraglenoid tuberosity, sharp and curved medially.

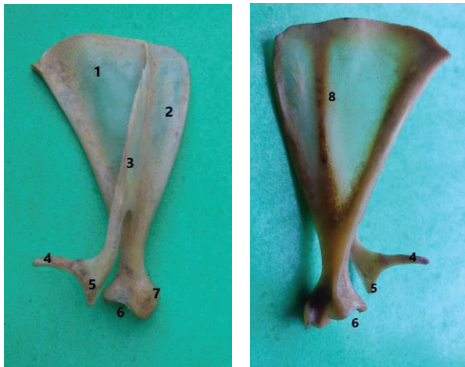

Figure 7. Scapula in rabbit - lateral view (left) and medial view (right) (original):

- 1 - infraspinous fossa; 2 - supraspinous fossa;
- 3 - scapular spine; 4 - paraacromion; 5 - acromion;
- 6 - glenoid cavity; 7 - supraglenoid cavity;
- 8 - subscapular fossa

The caudal angle of the scapula is thickened and tuberos, and the dorsal edge of this bone features a suprascapular cartilage.

The cranial angle of the scapula is slight and rounded.

The ventral angle appears thickened, and on the medial and lateral sides of the scapular neck vascular grooves can be observed.

The clavicle of this species is narrow, compared to the coypu where it appears well-developed.

The humerus is a long bone which, laterally to its articular head, exhibits the greater tubercle

where an articular surface for the clavicle is found. The bicapital groove is slightly deep.

The cranial side of its body appears plane and widened proximally, while the lateral side displays a light torsion groove. Caudally, the torsion groove is delimited by the ridge of the lateral epicondyle until its distal extremity where this ridge becomes thick and rough.

The distal extremity of the humerus has tall, sharp and equally sized trochlear lips, while the olecranon fossa appears deep (Figure 8). The presence of the supratrochlear hole was not noted in any of the bodies examined, even though it is described in the literature.

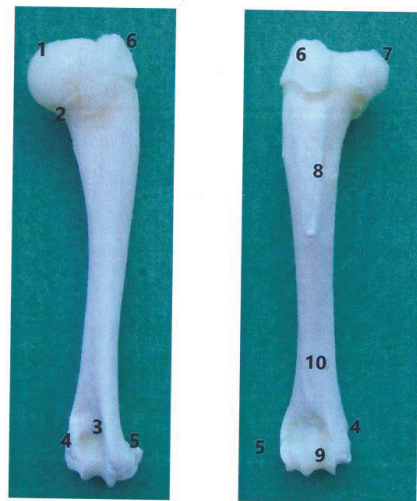


Figure 8. Humerus in rabbit - lateral view (left) and medial view (right) (original):

- 1 - humeral head; 2 - neck of humerus; 3 - olecranon fossa;
- 4 - medial epicondyle; 5 - lateral epicondyle;
- 6 - greater tubercle; 7 - small tubercle; 8 - deltoid tuberosity;
- 9 - humeral trochlea; 10 - brachial groove

The forearm bones of this species appear curved cranially and they are joined through an interosseous ligament. The proximal extremity of the radius has two diarthrodial articular surfaces and two glenoid cavities. Distally, the radius has a wavy carpal surface (Figure 9).

Concerning the proximal extremity of the ulna, the olecranon appears oriented cranially, with a wide semilunar notch. It has two diarthrodial articular surfaces. The ulna has a distal joint with the carpal bones from the first row (Figure 10).

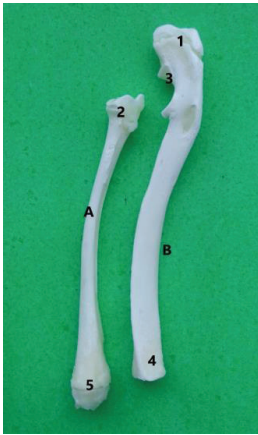


Figure 9. Radius and ulna in rabbit (original):
 A - radius; B - ulna;
 1 - olecranon; 2 - proximal extremity of radius;
 3 - semilunar notch; 4 - distal extremity of radius;
 5 - distal extremity of ulna



Figure 10. Radius and ulna in rabbit - cranial view (original):
 1 - olecranon; 2 - olecranon tuber; 3 - radial articular surface; 4 - interosseous space of forearm (proximal and distal); 5 - distal extremity of ulna; 6 - distal extremity of radius

The basipodium of the rabbit features, between the two rows of carpal bones, a central bone. The pisiform is elongated and has two articular surfaces for the pyramidal bone and for the distal extremity of the ulna. The pyramidal bone has articular surfaces for the semilunar, the pisiform, the ulna as well

as a distal extension to articulate with the V metacarpal. The semilunar bone has a dorsal convex articular surface and a palmar concave one. The scaphoid bone has an articular area for the semilunar bone represented by two elongated articular surfaces. The unciform is the most developed bone in the distal row. The capitate has proximal articular surfaces for the semilunar and the scaphoid. The trapezoid bone has an articular surface for the trapeze and for the I metacarpal.

Metacarpal I is reduced in size compared to the other 4 bones in the same segment. Each metacarpal has, on its proximal extremity, a plane and wide articular surface for the corresponding carpal bone in the distal row. The body of the metacarpals is slightly cylindrical. The distal extremity of metacarpal I has a depression on its medial side.

In the house rabbit, the first phalange is a long bone, whose proximal extremity is fitted with two glenoid cavities separated by a medial groove. Under the proximal articular surface, on the palmar side, two tubercles can be observed, disposed laterally and medially. At the distal extremity, the first phalange has two condyloid articular surfaces separated by a median groove. The proximal extremity of the II phalange has two articular cavities separated through an elongated ridge with dorso-palmar orientation. The distal extremity of phalanx II presents a trochlear surface for articulation. The distal phalange or the II phalanx (the claw) has two proximal articular cavities separated by a reduced ridge. There are two great sesamoids per each finger, and they articulate with the proximal extremity of the first phalange with a proximally oriented tip. The small sesamoid completes the proximal articular surface of the third phalange.

CONCLUSIONS

The clavicle of the rabbit is a narrow bone unlike in coypu where it is long and well-developed.

In coypu, the ratio of the supraspinous and infraspinous fossae of the scapula is 2/1.

The acromion is flanked by a short and tuberosus para-acromion.

The deltoid tuberosity appears exaggeratedly developed, approachable transcutaneous.

Contrary to the literature data, where it is described as being absent, in two of the three

investigated body corpses, the supratrochlear hole is evident at the distal extremity of the humerus.

In all the examined rabbit bodies the supratrochlear hole was not found, even though it is mentioned in the literature.

The distal phalanx presents a prismatic form, with a flexor tubercle on the ventral face, flanked axially and abaxially by a wide and deep intertubercular groove.

Between the forearm bones in coypu, a large interosseous space was noticed, which differentiates this species from leporids, where the interosseous space does not appear due to the two bones being articulated through an interosseous ligament along their entire length.

Both in coypu and in the rabbit, the thoracic basipodium is formed of 9 carpal bones due to the central bone which is located between the two rows of carpal bones.

REFERENCES

- Brewer N.R., Cruise L.J. (1994). Anatomy and Physiology. In: Manning PJ, Ringler DH, Newcomer CE, editors. The biology of the laboratory rabbit. San Diego. Academic Press; p. 63-71.
- Coțofan V., Hrițcu Valentina, Negrea S., Cura P., Cozariuc I. (1982). Caractere morfologice diferențiale ale scheletului axial la nutrie comparativ cu unele mamifere domestice. Lucr. Sem. Șt. „Metode noi de sporire a producției la animale”, Iași.
- Coțofan V., Cocoș Lucia, Cura P., Hrițcu Valentina, Negrea A. (1982). Caractere morfologice diferențiale ale oaselor membrului toracic la nutrie, comparativ cu unele mamifere domestice. Lucr. Sem. Șt. „Metode noi de sporire a producției la animale”, Iași.
- Coțofan V., Predoi G. (2003). Anatomia topografică a animalelor domestice. Editura Bic All, București.
- Harcourt-Brown F. (2002) – Textbook of rabbit medicine. Oxford, Butterworth-Heinemann.
- Hrițcu Valentina, Coțofan V. (2000). Anatomia animalelor de blană: nutria, dihorul. Editura Ion Ionescu de la Brad, Iași.
- Gheție V., Hillebrand A. (1971). Anatomia animalelor domestice, Vol. I. Editura Academiei Republicii Socialiste România.