

THE PREVALENCE OF HEMATURIA IN DOGS AND CATS

Alexandra Mihaela POPA¹, Valentina SIMION¹, Iuliana CODREANU¹
Cristina FERNOAGĂ¹, Mihai CORNILĂ¹, Mario CODREANU¹

¹University of Agronomic Sciences and Veterinary Medicine of Bucharest, 59 Mărăști Blvd, District 1, 011464, Bucharest, Romania, Phone: +4021.318.25.64, Fax: + 4021.318.25.67, Email: alexandrapopa613@gmail.com

Corresponding author email: alexandrapopa613@gmail.com

Abstract

This paper briefly reviews the basic definitions of hematuria, the common causes and the prevalence of this symptom on dogs and cats. This study was conducted in the Clinic of Faculty of Veterinary Medicine in the period between 1.10.2016 – 1.02.2017 using IDEXX UA dipstick, IDEXX VetLab UA, Refractometer RHCN-200ATC and Grant Bio PCV-2400 Combined Centrifuge. Data collected recorded 65 animals, with felines obtaining a percentage of 42% and canine 28% in regard of hematuria prevalence by species. In case of hematuria prevalence based on gender we registered 62% males and 38% females. In hematuria prevalence by age we listed 32% of animals cu age range between 6-10 years, 31% with 1-5 years, and also 31% over 10 years, and 6% less than a year. From a total of 51 urinary dipstick who tested positive, we discovered on the examination of urine sediment that 46 samples confirms, and 5 samples offered a false - positive. Of the 71 samples analyzed 76% were within the macroscopic hematuria and 24% to microscopic hematuria, and 28% of the samples showed no hematuria. As a conclusion hematuria is a common finding of urological pathology and it is important to know the risk factors of every species.

Key words: hematuria, prevalence, gross hematuria, microhematuria.

INTRODUCTION

Hematuria is defined as the presence of five or more RBCs per high-power (40x) field in a fresh, centrifuged specimens obtained by either manual compression of the bladder catheterisation, or cystocentesis (Reine et al., 2005).

Healthy animals can excrete as many as 3 red blood cells per high-power field (Chew, 2011). Hematuria is commonly subdivided according to its type as macroscopic hematuria (i.e., visible, named gross hematuria) and microscopic hematuria (Figure 1, Figure 3) (i.e., nonvisible detected with a microscope), time of micturition (initial, terminal or total), duration (intermittent or persistent) and the clinical form - symptomatic or asymptomatic (Costache, 2005).

Initial hematuria indicates the origin in urethra or prostate (males), total hematuria – in bladder, ureter, and kidneys, and terminal hematuria, bladder or prostate (Mazhari, 2002) (Figure 2).

Gross hematuria is suspected when urine is has an abnormal color, usually red or tea-colored. In evaluating gross hematuria, it is important to

confirm the presence of RBCs by microscopy (Massengill, 2008)

Microhematuria is often detected during investigation of symptoms such as dysuria, urinary frequency, or flank pain (Massengill, 2008).

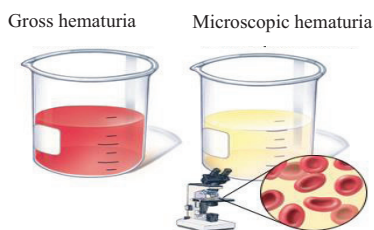


Figure 1. Gross hematuria vs. Microhematuria
<https://www.drugs.com/health-guide/hematuria.html>

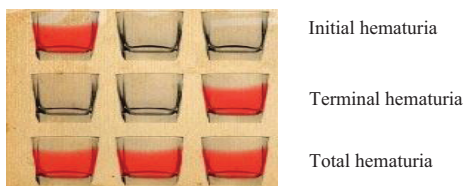


Figure 2. Hematuria. Time of micturition
<http://www.kidneyservicechina.com/pkd-symptoms/4325.html>




Figure 3. a Normal urine; b microscopic hematuria (+++); c macroscopic hematuria (Barrat, 2007).

“Dipstick hematuria” and “dipstick microhematuria” is a nondiagnostic screening test offering a positive result due to oxidation of a test-strip reagent (Rao and Jones, 2008). This paper briefly reviews the basic definitions of hematuria, the common causes and the prevalence of this symptom on dogs and cats. There are many causes of hematuria, and is a priority in the medical act for the doctor to discover the origin of hematuria by establishing whether its nature is renal or non-renal (Table 1).

Table nr. 1 Causes of hematuria

<i>Intrinsic Renal Disease</i>	<i>Non-Renal Disease</i>
Glomerulonephropathy	Ureteric (stones,tumor)
Cystic disease	Bladder
Renal tumors Interstitial disease Interstitial nephritis Papillary necrosis/analgesics Stones or crystals Acute infection	- tumors - stones - Cystitis) Prostate (carcinoma - Prostatitis)
Atrioventricular malformation	Urethral lesions

after (Fine, 2002)

Diagnosis of hematuria can be pronounced easily by using urine strips which evaluates for pyuria, proteinuria, heme positivity, and urinary concentrating defects (Table 2) and using microscopic examination of urine sediment by evaluating for white blood cells and clumps, RBC morphology, crystals, and casts. Crystalluria can be determined by calcium

oxalate, calcium phosphate, uric acid, or cystine crystals. Hypercalciuria is the most common cause of crystalluria (Massengill, 2008).

A reagent strip, also called a dipstick, is a narrow strip of plastic with small pads attached to it. Each pad contains reagents for a different reaction, thus allowing for the simultaneous determination of several tests. The colors generated on each reagent pad vary according to the concentration of the analyte present. Colors generated by each pad are visually compared against a range of colors on brandspecific color charts (Bataille et al., 2016).

Urine dipstick is used to test for the peroxidase activity of erythrocytes (Robert, 2007).

Table 2. Substances tested for by urine dipsticks

Commonly assessed	Commonly assessed Less commonly assessed
Blood Ketones	Blood Ketones
Protein Urobilinogen	Protein Urobilinogen
Glucose Bilirubin	Glucose Bilirubin
Leukocyte esterase Specific gravity	Leukocyte esterase Specific gravity

after (Barrat, 2007)

Urine culture is performed in cases that have clinical symptoms or laboratory evidence (pyuria, hematuria, bacteriuria, positive nitrites) of a urinary tract infection (Bataille et al., 2016).

Also in the assessment of patients that express hematuria, complementary tests should be performed such as blood pressure, evaluation of renal functional parameters and proteinuria (Van Der Molen et al., 2012).

If the test is positive for hematuria unaccompanied by urine abnormality it is necessary to determine serum creatinine. If it has a high value more tests will be done. The normal values of serum creatinine indicates the need for an ultrasound (Fine, 2002).

MATERIALS AND METHODS

This study was conducted in the Clinic of Faculty of Veterinary Medicine in the period between 1.10.2016 – 1.02.2017.

In order to establish the prevalence of hematuria in dogs and cats, fresh midstream urine samples (5-10 mL) were obtained from animals with urologic signs.

We evaluated 71 samples, 27 from feline and 18 from canine, 40 being males and 25 females, with age range between 4.5 months and 17 years. The urine samples were first evaluated macroscopically, and its color and clarity were recorded; then we used IDEXX UA dipstick for detecting the blood in IDEXX VetLab UA Analyzer and Clinical Refractometer RHCN-200ATC for measuring the urine specific gravity.

The change in the color were noted and compared with standard provided. After the macroscopic evaluation the samples were prepared for urine sediment examination by centrifugation for 10 minutes at 6000x in a Grant Bio PCV-2400 Combined Centrifuge. The supernatant fluid was decanted and a drop of sediment was transferred to a glass slide and a coverslip was placed on the specimen. The slides were examined at 400 magnification for red blood cells.

Hematuria was considered to be present at five or more RBCs per high-power (40x) field.

RESULTS AND DISCUSSIONS

In the study prevalence of hematuria on dogs and cats, we have taken in consideration parameters that influence the result and conclusion, such as species, age and gender.

In regard of hematuria prevalence survey considering species, our result was that 65 animals participated, and felines obtained a percentage of 42% and canine 28%.

Giving this result and from the diagnosis established, the felines are more prone to express hematuria, being liable to develop FUS (feline urological syndrome), urinary lithiasis and cystitis (Figure 4).

In case of hematuria prevalence based on gender we recorded a significant proportion of males which have registered a percentage of 62% followed by 38% females.

Based on the diagnosis discovered the percentage 62 % males with hematuria is slightly predictable being well known the frequency of urological pathology in males due to anatomical features of lower urinary tract (Figure 5).

The males who participated in this survey most were diagnosed with urinary lithiasis and FUS.

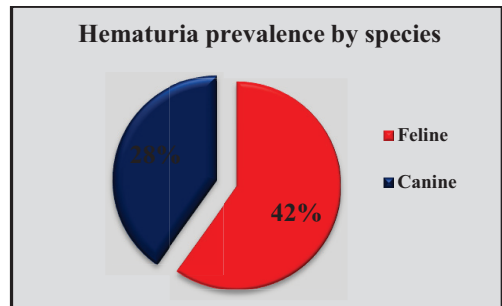


Figure 4. Hematuria prevalence by species (Original)

Females who manifested hematuria were diagnosed majority of them with cystitis, microlithiasis and just one case with glomerulonephritis and FUS.

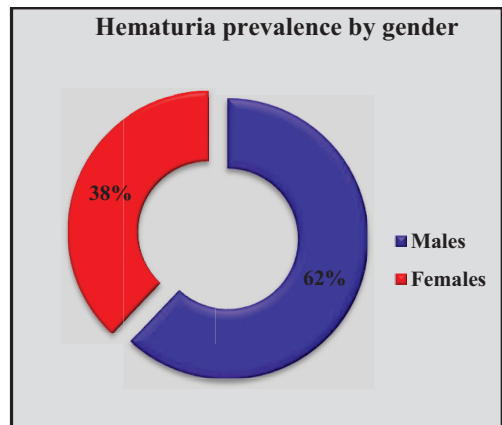


Figure 5. Hematuria prevalence by gender (Original)

Hematuria was encountered in different ages of the subjects, in a prevalence of 32% of animals with age range between 6-10 years, 31% with 1-5 years, and also 31% over 10 years, and 6% less than a year (Figure 6).

Other studies have concluded that risk-factors for stone formation, are age, gender and breed, together with influences such as geographical location, presence of UTI and dietary history (Syme, 2012).

Cystine urolithiasis occurs preponderantly (98%) in male dogs and are not common in very young dogs but tend to occur in middle-age (Syme, 2012).

The prevalence of cystine calculi is highly dependent on geographical location, with a higher reported prevalence in dogs in Europe than dogs from the USA (Syme, 2012).

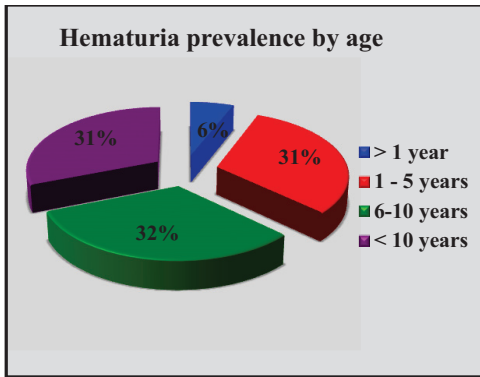


Figure 6. Hematuria prevalence by age (Original)

We evaluated 65 animals from which we collected 71 samples on a period of 5 months; the result we obtained using urinary dipstick IDEXX UA, was 51 tested positive for RBC/hemoglobin/ myoglobin - urine is discolored but no RBC are noted on microscopic examination (Figure 7).

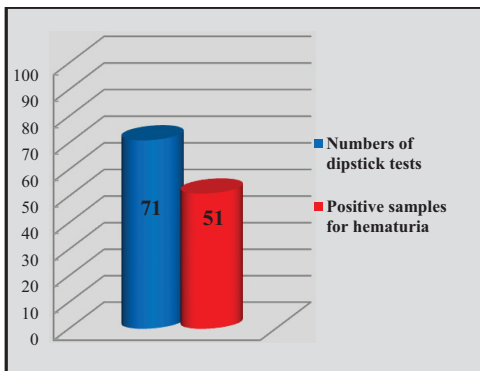


Figure 7. Numbers of dipstick test and positive samples for hematuria (Original)

It is been noted that microscopic hematuria is present when more than five red blood cells (RBCs)/high power field are found (Fine, 2002). Dipstick testing is the initial test for detecting hematuria. It is very sensitive and will pick up one to two RBCs/hpf (Fine, 2002). Dipstick testing will register positive in a urine that has microscopic hematuria allowed to stand for too long (*i.e.*, with hemolyzed RBCs)

in spite of few or no red cells being seen on the film. In some cases, dipstick tests provides a false negative or false positive (Choi, 2003). Table 3 summarizes the main causes in appearance of urine strips errors (Fine, 2002).

Table 3. Reasons in appearance of urine strips errors*

Reasons blood shows on dipstick urinalysis but not on microscopic exam (false positive)	Reasons blood doesn't show on dipstick urinalysis but is present on microscopic exam (false negative)
Exercise	Captopril Vitamin C
Dehydration	Acidic urine (pH <1.5)
Hemoglobin (part of red blood cell) Myoglobin (break down product of red blood cell)	Concentrated urine Protein in the urine dipstick exposed to air

after (O'Brien et al., 2014).

The protocol in the diagnosis of hematuria includes first testing with urinary strip and if it is positive urine should be sent for urinalysis. If the patient has more than five RBCs/hpf, microscopic hematuria is present.

The American Urologic Association declares "evaluation should be based solely on findings from microscopic examination of urine sediment and not on a dipstick reading." (O'Brien et al., 2014).

From a total of 51 urinary dipstick who tested positive, we discovered on the examination of urine sediment that 46 samples confirms the presence of more five red blood cells (RBCs)/high power field, and 5 samples offered a false - positive (Figure 8).

Positive dipstick for hematuria with negative microscopy are often due to false negative microscopy. With bright field microscopy, negative results may occur as a result of spontaneous lysis of red cells or by failure to detect 'ghost' forms (Choi, 2003).

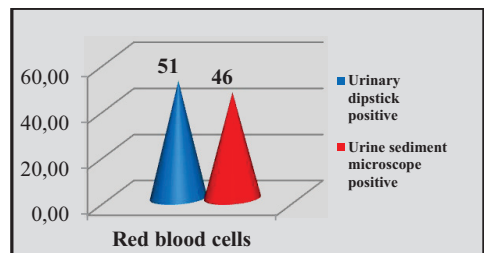


Figure 8. Urine dipstick positive vs. Urine sediment microscope positive (Original)

Of the 71 samples analyzed it was determined that 76% were within the macroscopic hematuria and 24% to microscopic hematuria, and 28% of the samples showed no hematuria (Figure 9).

In assessing gross hematuria, it is important to verify the presence of RBCs by microscopy. After centrifugation of the urine, the finding of red urinary sediment with a positive strip test for hemoglobin it suggest hematuria, whereas red supernatant with negative dipstick testing for hemoglobin is indicative of myoglobinuria, hemoglobinuria, or other causes of discolored urine (Veerreddy, 2013).

The overwhelming result in which macrohematuria is triple to microscopic hematuria is probably due to the fact that most of the diagnosis established implies o advanced pathological disorder in which bleeding is a common sign .

Concerning the micturition moment, terminal hematuria records a higher proportion, being an element suggesting the involvement of the lower urinary tract.

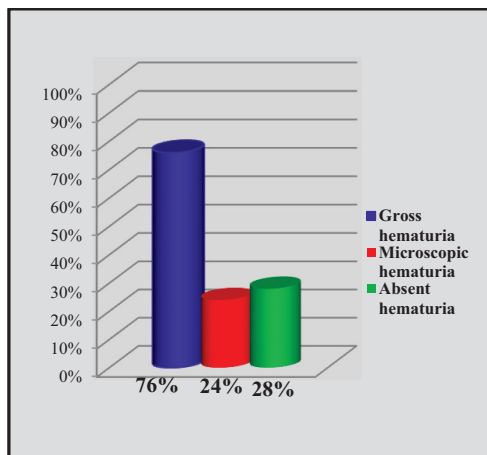


Figure 9. Gross hematuria and microhematuria (Original)

CONCLUSIONS

Hematuria is a common finding of urological pathology as we discovered in our study. Hematuria in dogs and cats has a wide differential diagnosis, with different therapeutic approaches compared to human patients.

It is important that in the first evaluation of the animals the clinician takes account of the risk factors of every species.

Knowing that felines with male gender are prone to develop urological disorders that express macroscopic hematuria such as FUS, urolithiasis and cystitis, can help the clinician to pursue a reduced number of methods of investigation offering a fast diagnosis.

More often than not, owners, demand an immediate diagnosis, particularly when there is macroscopic hematuria due to the impact of blood in the urine that alarms them.

A simple and practical approach to the animal who presents hematuria should consists in a fewer invasive studies, a less costly evaluation, and a accurate diagnosis.

Our results suggest that asymptomatic microscopic hematuria in dogs and cats is rarely associated with clinically significant disease of the urinary tract, but is mandatory to keep under observations the animals.

Gross hematuria is more commonly and is associated with urinary tract disease, such that a thorough evaluation for determination of the bleeding origin is justified and recommended.

REFERENCES

- Barratt, J., 2007. What to do with patients with abnormal dipstick urinalysis. *Medicine*, 35(7),365–367.
- Bataille, A., Wetzstein, M., Hertig, A., Vimont, S., Rondeau, E., & Galichon, P., 2016. Evidence of dipstick superiority over urine microscopy analysis for detection of hematuria. *BMC Research Notes*, 9(1), 435
- Chew, D. J., DiBartola, S. P., & Schenck, P. A., 2011. Urinalysis. *Canine and Feline Nephrology and Urology*, 1–31.
- Choi, K., 2003. Approach to Proteinuria and Hematuria in General Practice Urine microscopy – the Liquid Biopsy . *Hematuria*, 1–7
- Costache, C., 2005. Hematuria - algoritm de diagnostic, 1(3), 265–270.
- Fine, B. A., 2002. Hematuria,143–147.
- Massengill, S. F.,2008. Hematuria. *Pediatrics in Review*, 29(10), 342–348.
- Mazhari, R., & Kimmel, P. L., 2002. Hematuria : An algorithmic, 69(11).
- O'Brien, W., O'Connor K., Lailas N., Schenk G., Young J., Pruna C., Starks C., Spencer J., Tamburro K., Cage K., Parker M., 2014. The urology group, 30, 2011.
- Rao, P. K., & Jones, J. S., 2008. How to evaluate “dipstick hematuria”: What to do before you refer. *Cleveland Clinic Journal of Medicine*, 75(3), 227–233.
- Syme, H. M., 2012. Stones in cats and dogs: What can be learnt from them? *Arab Journal of Urology*, 10(3), 230–239.

- Reine, N. J., & Langston, C. E., 2005. Urinalysis interpretation: How to squeeze out the maximum information from a small sample. *Clinical Techniques in Small Animal Practice*, 20(1 SPEC.ISS.), 2–10.
- Roberts, J. R. (2007). Urine Dipstick Testing: Everything You Need to Know Urinalysis: A Comprehensive Review. *Emergency Medicine News*, 29(June), 24–27.
- Van Der Molen, A. J., & Hovius, M. C., 2012. Hematuria: A problem-based imaging algorithm illustrating the recent Dutch Guidelines on Hematuria. *American Journal of Roentgenology*, 198(6), 1256–1265.
- Veerreddy, P., 2013. Hemoglobinuria misidentified as hematuria: Review of discolored urine and paroxysmal nocturnal hemoglobinuria. *Clinical Medicine Insights: Blood Disorders*, 6, 7–17.