

ELECTRORETINOGRAPHY: SELECTION OF PATIENTS AND PERFORMING THE TECHNIQUE

**Adina ARGASEALA, Lia ION, Gina GIRDAN, Ion Alin BIRTOIU,
Jacqueline MOCANU, Iuliana IONASCU**

Faculty of Veterinary Medicine of Bucharest, 105 Independence Street, District 5,
Bucharest, Romania

Corresponding author email: adina.argaseala@gmail.com

Abstract

Electroretinography (ERG) is an objective test that evaluates the retinal function. This paper wants to present to the veterinary Romanian scientific community the importance of using this diagnostic tool for clinicians dealing with blind patients. Candidates for ERG were selected from ophthalmological patients presented with blindness because it was difficult to establish a definitive diagnosis using only ophthalmological examination. All patients underwent general anesthesia. ERG was performed using the HMsERG unit, with preprogrammed included protocols. The protocols used in this study were Short protocol for the cataract surgery candidates and ISCEV protocol for the other patients. ERG confirmed the results obtained on chromatic pupillary light reflex evaluation. ERG proved useful in the following cases: diagnosing retinal inherited disorders, differentiating between retinal and postretinal causes of blindness, evaluation of retinal function in cataract surgery candidates. ERG objectively assesses the retinal function and should be used on a larger scale by practitioners dealing with blind patients.

Key words: electroretinography, retina, blindness, cataract.

INTRODUCTION

The flash electroretinogram (ERG) is an electrodiagnostic test that assesses the function of one part of the central nervous system, the retina (Gelatt et. al, 2013) and it is described as the electrical response recorded when the retina is stimulated by flashes of light (Maggs et al., 2008).

This technique is useful for the early diagnosis and prognosis of inherited progressive retinal atrophy (PRA) or characterizing retinopathy due to other causes.

ERG is also useful when it is performed before cataract surgery as well as in diagnosing specific blinding disorders in dogs, such as sudden acquired retinal degeneration, optic neuritis or cortical blindness (Narfstrom et al., 2002).

Although ERG is a widely used technique in veterinary ophthalmology, this paper wants to present to the veterinary Romanian scientific community the importance of using this diagnostic tool for clinicians dealing with blind patients.

MATERIALS AND METHODS

Candidates for ERG were selected from the patients presented with blindness in the Ophthalmology Department of the Faculty of Veterinary Medicine of Bucharest, during December 2016 – February 2017. They were divided into 3 groups, based on clinical findings: partially blind patients, completely blind patients and cataract surgery candidates. After clinical assessment, serological and hematological examinations were performed. Ophthalmological examination included Schirmer tear test, fluorescein test, visual testing (menace response, cotton ball test, obstacles test), tonometry, pupillary light reflex, chromatic pupillary light reflex, ophthalmoscopy. In some cases complementary diagnostic tests have been used, such as ultrasound and MRI.

The chromatic pupillary light reflex (chromatic PLR) is a useful method for detecting PLR abnormality in sudden acquired retinal degeneration (SARDS), progressive retinal atrophy (PRA), or optic pathway disease, thus distinguishing between these 3 diseases that all present with blindness (Terakado et al, 2013; Yeh et al., 2017).

Therefore, evaluation of the chromatic PLR in blind patients can suggest a possible diagnosis prior to ERG or MRI examination.

Prior to anesthesia, both pupils were dilated by applying one drop of 1% tropicamide (Tropicamida 1%; Rompharm, Romania) and phenylephrine 10% (Fenefrin 10%; UnimedPharma, Slovakia) three times, with a 10 minutes interval between instillation of the drops.

The patients were fully anesthetized in order to prevent artifacts due to involuntary muscles movement (Ekesten et al., 2013).

Dogs were premedicated with dexmedetomidine (2-10 mcg/kg) (Dexdomitor 0,5 mg/ml; Orion Pharma, Finland) and butorphanol (0.2-0.4 mg/kg) (Butomidor; Richterpharma, Austria), delivered intramuscularly. Induction and maintenance were achieved using propofol initial bolus (1 mg/kg) (Norofol 1%; Maravet, Romania) and a constant rate infusion of 0.1-0.5 mg/kg/min intravenously.

Cats were premedicated using dexmedetomidine (0.01 mg/kg), ketamine (2 mg/kg) (Anestamine 100 mg/ml; LeVet Pharma, Holland) and butorphanol (0.2 mg/kg) administered intramuscularly. Induction and maintenance were achieved using propofol initial bolus (4 mg/kg) and a constant rate infusion of 0.6 mg/kg/min.

Local nerve blocks of the auriculopalpebral and zygomatic nerve were performed on all patients, using lidocaine (1-2 mg/kg) (Xilina 10mg/ml; Zentiva, Romania).

Topical anesthesia was induced using 0.4% oxybuprocaine hydrochloride (Benoxi 0.4%; UnimedPharma, Slovakia).

Each patient was placed in sternal recumbency. Eyelids were kept open during the examination with a lid speculum (Barraquer eye speculum; Acrivet, Germany) and globes were centered with 1-2 conjunctival stay sutures.

ERGs were recorded using the Handheld Multispecies ERG system (HM_sERG, RetVetCorp, USA) consisting of the unit body, a mini Ganzfeld dome and three electrodes (active, reference and ground electrodes).

Retinal signals were recorded using a contact lens active electrode (ERG-jet; Fabrial, Switzerland) that was placed on the cornea after applying artificial tear gel (Hypromelozza P 0.5%; UnimedPharma, Slovakia), in order to improve conduction. The reference and the

ground electrodes were skin needles electrodes (Stainless steel subdermal electrode; OcuScience, USA) that were placed approximately 2 cm caudal to the lateral canthus and in the midline on the top of the skull, respectively. Electrodes were kept in a stable position using a piece of tape. All 3 electrodes were connected to a preamplifier and the signals were amplified with a bandpass of 0.3 to 300 Hz, provided by the HM_sERGunit.

Impedance and baseline tests were performed before ERG recordings. The electrode impedance was maintained under 5 k Ω and the baseline test under 25 microvolts.

A handheld mini Ganzfeld dome, positioned approximately 1 cm to the eye, without touching the animal, provided light stimuli and background adaptation.

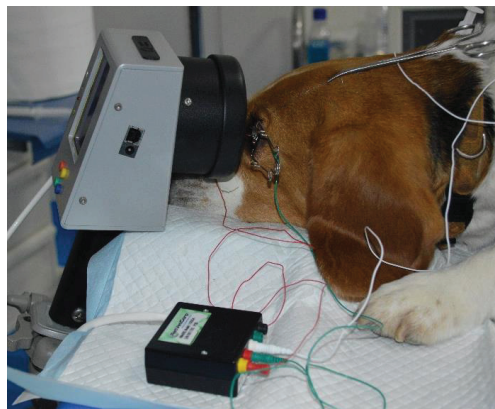


Figure 1. ERG setup using the HM_sERG device.

The HM_sERG system software package has several preprogrammed protocols for evaluating retinal function. We used the ISCEV Protocol for patients with partial or complete blindness and the Short Protocol for cataract surgery candidates.

Before performing the ISCEV Protocol, the patients were dark adapted for 20 minute. For the Short Protocol, the patients were light adapted. All lights in the examining room were turned off at the ERG test initiation.

According to the HM_sERG user's manual, for rods' function evaluation, responses for scotopic ERG procedures were recorded using low intensity stimuli (0.01 cd.s/m² of light stimuli), scotopic standard intensity responses

(Std R&C) using 3 cd.s/m² of light intensity for stimulus, scotopic higher intensity responses (Hi-Int R&C) using 10 cd.s/m² of light intensity to stimulate both rods and cones. For cones' function evaluation, responses for photopic ERG procedures were recorded using light stimuli of 3 cd.s/m², scotopic higher intensity responses (HiCones) using 10 cd.s/m² of light intensity, flicker responses using 3 cd.s/m² of light intensity for standard flicker (Std. Flicker) and 10 cd.s/m² of light intensity for higher intensity flicker (Hi-Int. Flicker). ERG data for each patient were recorded bilaterally. ERG recordings were analyzed by measuring the amplitude and implicit time for each a- and b-wave ERG component, as well as the b/a ratio.

The a-wave amplitude was measured from the baseline to the a-wave trough, the b-wave amplitude was measured from the a-wave trough to the b-wave peak. A- and b-wave implicit times are calculated from the light stimulus onset to the a-wave trough and b-wave peak, respectively. Amplitude of the cone flicker response represents the average of the amplitudes from the trough to the positive peak in at least 3 responses in the train. Implicit time of the cone flicker response is calculated as the average of the times from the light onset to the positive peak in at least 3 responses in the train. (Ekesten et al, 2012). For the scotopic low intensity responses and photopic 30 Hz flicker responses, only the b-wave amplitude and implicit time were measured.

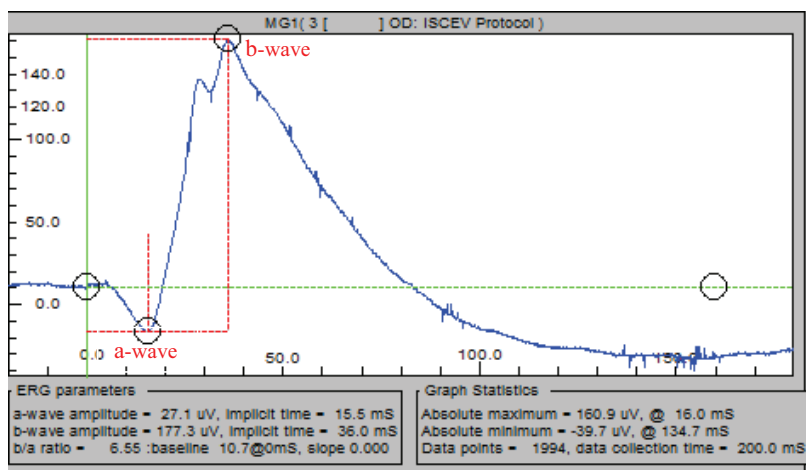


Figure 2. A- and b-wave parameters in a normal ERG, DSH, 4 years old. The vertical green line represents the stimulus onset

RESULTS AND DISCUSSIONS

Although different from other anesthetic protocols usually used for ERG recordings, the protocol that we used assured appropriate anesthesia for ERG examination. None of the patients were intubated during ERG evaluation. Because atipamezole can be used to counter the effect of dexmedetomidine if needed and because propofol is a short action drug, we believe that this protocol is safe. Furthermore, if after ERG recordings, further cataract surgery or MRI examination is needed, the anesthesia can be maintained by intubating the patients.

Local anesthetic blocks provided good anesthesia, no blinking was recorded, thus reducing the artifacts to minimum.

The HMsERG device has built in protocols based on the International Society for Clinical Electrophysiology of Vision (ISCEV) guidelines. We chose the Short Protocol for the cataract patients, due to the fact that we only needed confirmation whether the retina is functional or not and because of the shorter time necessary to perform it. The ISCEV protocol was used in the cases where we needed a more complex investigation of the retina, separating the rods' responses from the cones' responses.

All results were compared with the normal ERG recorded in our clinic for the same species and age group and also compared to specialty literature data (Figure 2).

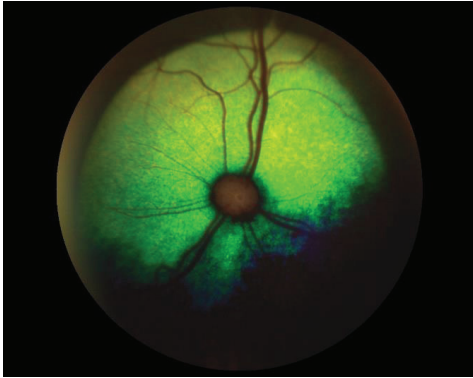


Figure 3. The normal fundus of a cat (DSH, 4 years old)

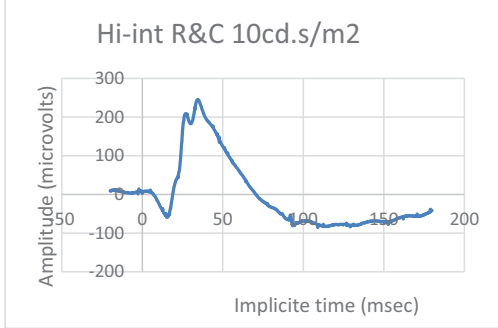


Figure 4. Normal ERG of the same cat

For the selected ophthalmological patients included in this paper, except for the cataract surgery candidates, it was difficult to establish a definitive diagnosis using only ophthalmological examination.

In patients which were presented with partial or complete blindness and with ophthalmoscopic modifications, ERG was used to confirm the absence of retinal function, establishing the diagnosis of early or late onset retinal degeneration (Figure 5 and Figure 6).

Two of the patients presented with acute blindness, complete mydriasis, unremarkable fundus examination and unresponsive pupils to the chromatic PLR suggesting optic neuritis. For these patients, ERG recordings proved to be an invaluable tool, diagnosing decreased retinal function, suggesting combined autoimmune retinal and optic nerve disease (Figure 7 and Figure 8).

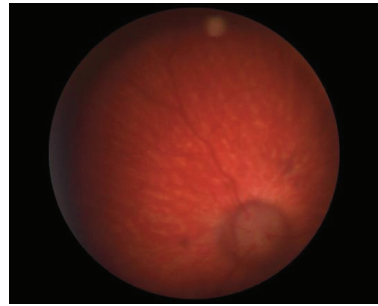


Figure 5. Fundus examination in a blind 6 months old Husky revealed vasculature attenuation.

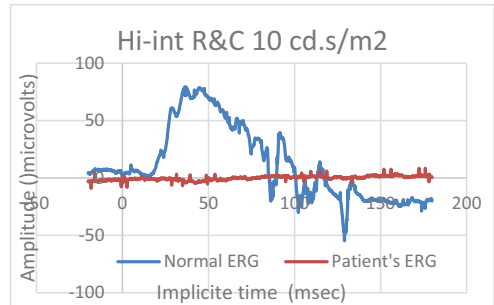


Figure 6. The electroretinogram of the Husky confirmed absence of retinal function, consistent with early onset retinal degeneration (PRA)

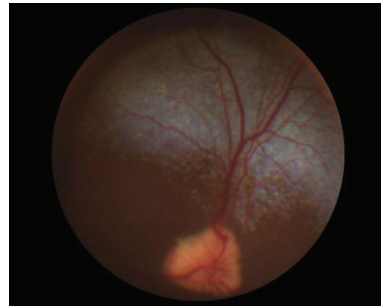


Figure 7. Normal fundus appearance of a blind 7 years old French Bulldog

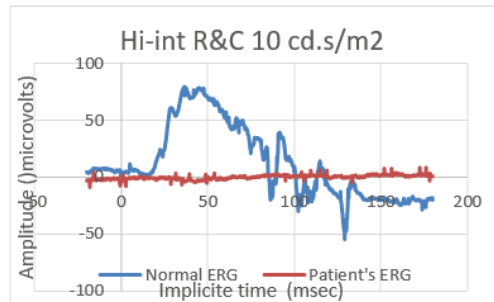


Figure 8. The electroretinogram of the French Bulldog showed decreased retinal function, consistent with an autoimmune mediated retinitis

One patient presented with partial blindness. Visual tests were negative in the affected eye, pupils were mydriatic in ambient light and the chromatic PLR was normal in both eyes. An ERG was performed and it showed normal retinal function. The MRI examination confirmed a postretinal cause of blindness, tumor of the coroidal plexus and ventricular hydrocephalus.

Five patients that were candidates for cataract surgery, were first examined by ERG. A good candidate for surgery has normal retinal function (established by chromatic PLR and ERG) and the lens in a normal, anatomical position. The retinal function responses that were recorded helped us in selecting the better candidates for surgery, as the ones with low a- and b-wave amplitudes and implicit time were excluded. One of these patients had normal, prompt and complete chromatic PLR, but due to the low retinal function recorded by the ERG, it was excluded from cataract surgery (Figure 9).

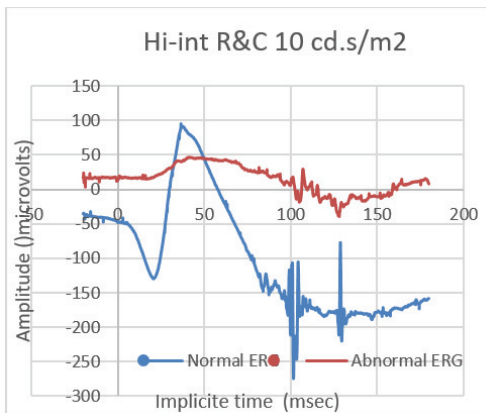


Figure 9. Differences between ERGs of two cataract surgery candidates. If the electric response of the retina is good, the patient is then operated (blue line). If the electric response of the retina is low, the surgery is not recommended (red line)

CONCLUSIONS

Electroretinography objectively evaluates the retinal function.

Candidates presented with blindness were diagnosed with retinal inherited disorders, differentiating between retinal and postretinal causes of blindness.

Evaluation of retinal function of cataract surgery candidates proved very useful in deciding whether the surgery is recommended. ERG should be used on a larger scale by practitioners dealing with blind patients.

REFERENCES

- Ekesten B., Komaromy A.M., Ofri, R., Petersen-Jones S.M., Narfstrom K., 2013. Guidelines for clinical electroretinography in the dog: 2012 update. *Doc Ophthalmol* 127:79–87.
- Gelatt K.N., Gilger B.C., Kern T.J., 2013. *Veterinary Ophthalmology*, 5th edition, Vol. 1, Wiley-Blackwell, UK, 684.
- Maggs, D.J., Miller, P.E, Ofri, R., 2008. *Slatter's Fundamentals of Veterinary Ophthalmology*, 4th Edition, Elsevier, Missouri, 293-294.
- Narfstrom, K., 2002. Electroretinography in veterinary medicine –easy or accurate? *Vet Ophthalmol*, 5, 249-251.
- Terakado K., Yogo T., Nezu Y., Harada Y., Hara Y., Tagawa M., 2013. Efficacy of the Use of a Colorimetric Pupil Light Reflex Device in the Diagnosis of Fundus Disease or Optic Pathway Disease in Dogs. *J. Vet. Med. Sci.* 75(11): 1491–1495.
- Yeh C.Y., Koehl C.L., Harman C.D., Iwabe S., Guzman J., Petersen-Jones S.M., Kardon R.H., Komaromy A.M., 2017. Assessment of Rod, Cone, and Intrinsically Photosensitive Retinal Ganglion Cell Contributions to the Canine Chromatic Pupillary Response. *Invest Ophthalmol Vis Sci.*, 58:65–78.