

## HYDROCEPHALUS IN FEMALE FRENCH BULLDOG CASE PRESENTATION

**Laura DARIE, Anca BULAI, Laura DUMITRU,  
Mihai Cornilă, Cristina FERNOAGĂ**

University of Agronomic Sciences and Veterinary Medicine of Bucharest,  
Faculty of Veterinary Medicine, 105, Splaiul Independentei,  
District 5, Bucharest, Romania

\*Corresponding author email: lauradarie1@yahoo.com

### **Abstract**

*The patient named Kim, a female French Bulldog was presented to the doctor since the age of two months. She attended a deworming and vaccination complete scheme. Over the time, she went through an episode of paraparesis which led to the diagnosis of lesions in the T3-L3 column section (resulting from RX). After a few months, neurological signs have emerged from the forebrain. After performing the clinical and neurological examination, an investigation that would exclude some conditions (differential diagnosis based on the acronym "VITAMIND"), a brain MRI was performed. The diagnosis was hydrocephalus. As a result, this case brings together two anomalies: one at the brain level and the other from the spine. Each new sign the owner described, was completed every time with clinical and neurological examination which led to a correct neurological diagnosis. The treatment was initiated immediately and was adjusted according to patient response to one of the prescription medications (acetazolamide).*

**Key words:** neurologic, hydrocephalus, abnormality, spine, acetazolamide.

### **INTRODUCTION**

Hydrocephalus is an active distension of the ventricular system of the brain resulting from an inadequate passage of CSF from its point of production within the ventricles to its point of absorption in the systemic circulation.

Loss of brain parenchyma may result in a secondary increase in ventricle size, which has been termed as compensatory hydrocephalus or hydrocephalus ex vacuo.

A congenital predisposition exists in many miniature breed dogs, Bulldogs and Boston Terriers.

The condition may be congenital due to obstruction of ventricular drainage (often at the level of the mesencephalic aqueduct) or decreased absorption of CSF due to dysfunction of the arachnoid villi, or it may be the result of secondary obstruction due to acquired disease (e.g. neoplasia, infection or inflammation).

Hydrocephalus may be secondary to CSF overproduction (e.g. choroid plexus tumor [rarely]) or increased viscosity of CSF due to elevated CSF protein content seen with some

tumors and the 'dry-form' of FIP in cats (Lahunta and Glass, 2009).

Hydrocephalus is described here because it involves the accumulation of excessive amounts of CSF in the brain or cranial cavity. In fact, the correct definition of hydrocephalus is any increase in the volume of CSF, which means that it is not always related to the cause of any neurologic signs.

A number of terms have been used over the years in reference to hydrocephalus, with varying usefulness (Platt and Garosi, 2012):

- internal hydrocephalus is a ventricular distention with CSF accumulation.
- external hydrocephalus is a subarachnoid space distension with CSF accumulation. This is also referred to as hydrocephalus ex vacuo.
- non-communicating hydrocephalus is a ventricular dilation due to an intraventricular obstruction of CSF flow preventing the communication between the ventricular system and the subarachnoid space.
- communicating hydrocephalus is a ventricular dilation secondary to an extraventricular obstruction of CSF flow.

- normotensive hydrocephalus is associated with an increase in CSF pressure.
- hypertensive hydrocephalus is associated with an increase in CSF pressure.
- the two major categories of hydrocephalus are compensatory and obstructive.

Hydrocephalus results in diffuse cerebral and/or brainstem signs due to cortical compression and elevated ICP. Most commonly, animals have altered mentation, inappropriate behavior, cortical blindness and seizures.

A ventrolateral strabismus is common. Hydrocephalus may be asymptomatic in milder cases. Congenitally affected animals often have a skull deformity (dome-shaped) and persistent fontanelles (Platt and Garosi, 2012).

Although developmental obstructive hydrocephalus occurs sporadically in all breeds of dogs, there is a much higher incidence in the toy and brachycephalic breeds, especially in the Chihuahua, Pekingese, Pug, Boston terrier, Yorkshire terrier, Pomeranian and English or French Bulldog.

This disorder is uncommon in cats. Despite the presumed fetal genesis of the obstruction, clinical signs may not be evident at birth.

Most will be observed by 3 months of age, some between 3 and 12 months, and rarely beyond 12 months. Some dogs exhibit no clinical signs despite markedly enlarged lateral ventricles with significant cerebral atrophy.

This suggests that the clinical signs may be related to the level of CSF pressure, which can be quite variable in these dogs (Lahunta and Glass, 2009).

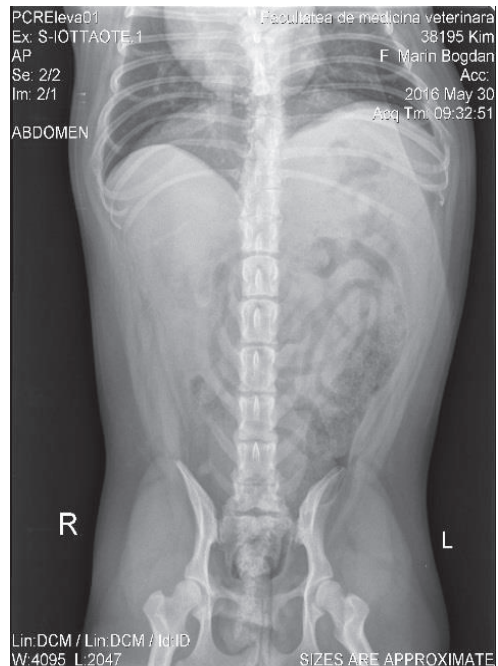
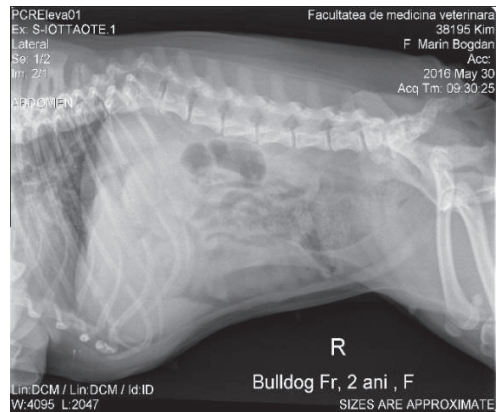The most common clinical signs observed are prosencephalic in origin because of the severe expansion of the lateral ventricles, with compromise of the cerebral tissue and compression of the diencephalon (Lahunta and Glass, 2009).

## MATERIALS AND METHODS

The patient was presented to the doctor at the Veterinary Faculty on April 5<sup>th</sup> 2015. The following investigations were performed:

- anamnesis (history);
- clinical and neurological examination;
- cardiologic exam;
- ophthalmological examination;
- biochemical examination;

- NH<sub>3</sub> and bile acids;
- hematological examination;
- abdominal ultrasound;
- 4DX Test;
- performed an X-ray on the spinal column T3-L3 (Figure 1)
- toxoplasmosis test – IgG and IgM (Figure 2).
- cerebral MRI.




**Figure 1.** T8-T10-T13 Hemivertebrae. T7-T9 united spinous processes. Spinous processes sclerosis at T11-T10. Deposition of new bone on the surface of the ventral vertebral bodies at T12-L2 level. Transitional vertebra - S1 (S1 vertebra lomberization), (dr. Nicolae Tudor permission)

**Buletin de rezultate**

Nume pacient: **Kim**

Specie: Caine  
 Rasa: Bulldog francez  
 Varsta: 1 ani 6 luni  
 Sex: F  
 Proprietar: Marin Bogdan  
 Adresa:  
 Data recoltarii: 25/08/2016 19:26

Contract:  
 Doctor: Fernoaga Cristina  
 Institutie:



Cod de bare: **9900045964**  
 Data inregistrarii: **25/08/2016**  
 Numar cerere: **99000203058**  
 Recoltat: **External**  
 Punct de recoltare:  
 Adresa:  
 Data rezultat: **01/09/2016**

Valori in afara limitelor admise pentru varsta si sexul respectiv

| Denumire                           | Rezultat | UM | Interval de referinta |
|------------------------------------|----------|----|-----------------------|
| <b>IVD Germania</b>                |          |    |                       |
| <b>Toxoplasma gondii IgG + IgM</b> |          |    |                       |
| <i>Ser / Imunofluorescenta</i>     |          |    |                       |
| Toxoplasma gondii IgG              | <1:64    |    | <1:64                 |
| Toxoplasma gondii IgM              | <1:64    |    | <1:64                 |

**Figure 2.** Toxoplasmosis test- negative IgG and negative Igm

## RESULTS AND DISCUSSIONS

In the Medical Clinic there has been presented a French Bulldog female of two and a half years old, named Kim. She was adopted by her owners when she was 2 months old and she followed the vaccination program according to age, being dewormed internally at 4 months and externally every month. She grew and developed normally.

She received good quality food and her playing partner was a cat. At 6 months she had a 2 week period when she experienced a secretion in the right ear (unilateral otitis), but it was treated (with an ear drops solution containing an anti-inflammatory and an antibiotic) and got cured.

The first signs of abnormal manifestations appeared at the age of 8 months, as follows:

- heavy walking on back legs (paraparesis);
- modified proprioception on both hind limbs: delay on flexion-extension test;
- normal spinal reflexes;
- hind limbs show contracture and spinal ataxia;
- light kyphosis;
- doesn't climb stairs up or down.

Neurological diagnosis: affection on the spinal cord T3-L3.

The administered treatment was Prednisolon 0,8 ml; then 10 days she underwent treatment with Aflutop 1 ml/day, IM.

After 10 days she showed a complete recovery. Maintenance treatment has been done with Arthrovit HA 1cps / day, MSM / 12 h , K9 Complete Motion 1 / day and Ganoderma for 3 months.

A month after beginning the treatment, she showed heavy walking, no pain when touching the spine and no proprioception changes. The treatment continued for another 3 months.

She had not shown neurological manifestations for 4 months. One month after stopping the previous treatment, in March 2016, the owner noticed that she had begun insistently licking on both forelimbs. She did not show any lesions or alopecia.

She resumed treatment with Arthrovit HA and K9 and added Pentoxiphiline at 50 mg / day to improve peripheral circulation.

Also in March 2016, she was sterilized with inhalatory anesthesia. She did not show any problems during surgery and the recovery was fast.

Although she followed a treatment with Atopivet 1 cps / day for 30 days, she followed a diet with z/d Hill's and had general baths with chlorhexidine 2 times / week for 4 weeks. Until July 2016 the licking persisted.

Since July 2016 changes in behavior have appeared. The owner described the changes as: the " crisis" began in June, at first very violent but with short duration. The crisis was represented by a very loud growl, barks and

heavy breathing. The crises were started throughout the day but at night intensified. The crisis worsened and in early September they were continuously. If at first a crisis was between 5 and 15 minutes, at the beginning of September they sometimes lasted all night. The only days in which the Bulldog did not have any crisis were those in which she had been subjected to anesthesia for MRI and after she began a treatment with prednisone and furosemide after seizures came back again with intensity increasingly higher. and it noted that there is almost the same hour when crises arise are 19-20 pm, 2-3 am, 6-7 am. If she is kept locked in a room one day she has no seizure and that if we found in our presence the "crisis" is stronger.

As a way of reaction, they are combined: the shaken powerful head, lets her head down on the floor, stretches her neck up and aside, has uncontrolled movements as if she catches a fly, and especially very violent "crisis".

Now it seems she has no reaction to treatment as the crises are continuing in the same characteristics."

When this patient was examined, the result of the neurological exam was:

- moments of nervousness;
- looking in an exact spot (fixed locations);
- catching "flies";
- sensation of "pinching" and jumping from a spot even when calm.

Focal epileptiform crises were suspected.

These had taken place only inside the house, outside having normal behavior. It was established a treatment with Gabapentin 10 mg/kg 2 times/day.

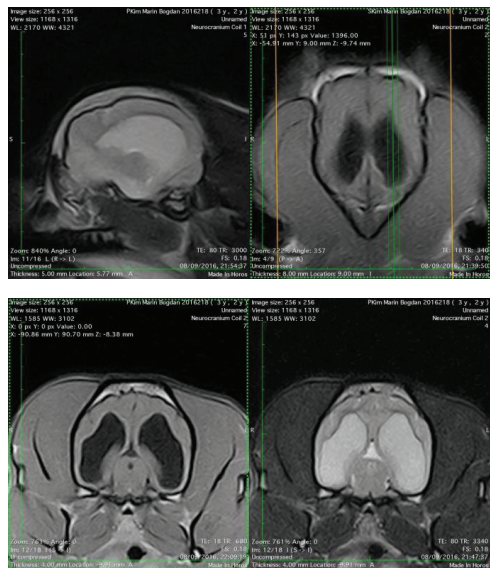
During the check-up from August 2016, the owner informed us that for the previous signs, she was supporting herself with her muzzle on the ground.

She continued the treatment with Gabapentin and performed a cerebral MRI in September 2016.

The results were:

- bilateral ventriculomegaly.
- suspicion of a slight enlargement of the mesencephalic aqueduct. No loading with contrast.

Conclusions: hydrocephalus, most probably congenital (Figure 3).



**Figure 3.** Bilateral ventriculomegaly hydrocephalus (dr. Florin Grosu permission)

The established treatment:

- Furosemid 40 mg 1 mg/kg /day;
- Prednisone 1 mg/kg/day;
- Omeprazole 10 mg/day (1mg/kg/day);
- Aspacardin ¼ cpr/day;
- Diazepam rectally when needed;
- Acetazolamide 10 mg/kg x 2 times/day.

After two weeks she came back for a check-up. Administering acetazolamide was stopped because the owner told that Kim was becoming very violent (according to the prospectus) after this medicine. Because the "crises" had become very frequent and lengthy (approximately 30 minutes) Levetiracetam at 10 mg / kg / 12 h , orally, was added to the treatment.

There have been added to the treatment:

- Phospholipids and ornytine;
- Omega-3 500 mg / day.

The "crises" have lost in intensity over time, but in December she was having "crises" between 6 and 9 pm, especially before having administered Diazepam rectally.

If Diazepam was not administered rectally, the crises would become more frequent and strong, therefore Diazepam was administered rectally 1-2 mg / day in the afternoon.

Fenobarbital at 4 mg / kg / day was added in order to remove Diazepam from the treatment. Ever since the outside temperature was low, Kim has felled much better. She still had crises

but were light and weak in intensity. She sometimes had up to 4 crises per day but was joyful, present and not aggressive.

For the neurologic examination from January 2017, changes were only noticed on cranial level: delayed reaction "of attention" (menace) at both eyes, eyelid reflex incomplete in both eyes.

## CONCLUSIONS

The medical history is very important and the data taken from the owner helped to establish a correct diagnosis.

The neurological examination was performed for each condition separately and was resumed on every recontrol. In the neurological observation sheet were noted the results of every done examination.

In this case, Kim had two different neurological diseases: one located in the brain (cerebral hemispheres) and another in the spine.

For the differential diagnosis the acronym "VITAMIND" was used and thus the anomaly

as the cause of the neurological signs in this case was chosen.

To obtain a correct diagnosis, a MRI was performed, which confirmed the presence of hydrocephalus.

The treatment for hydrocephalus was established according to the literature, but due to a reaction of the particular patient when taking acetazolamide, the treatment was adapted.

## REFERENCES

- Dewey C., 2003. A Practical Guide to Canine and Feline Neurology. Blackwell Publishing Professional House, Ames, 189-192.
- Lahunta A., Glass E., 2009. Veterinary neuroanatomy and clinical neurology. Saunders Publishing House, St. Louis, 67.
- Platt S., Garosi L., 2012. Small Animal Neurological Emergencies. Manson Publishing Ltd, London House, 147-150.
- <https://www.plumbsveterinarydrugs.com/#!/monograph/dErOnUrxGQ>