

THE INCIDENCE OF EPITHELIAL NEOPLASMS IN PETS (DOG AND CATS)

Iuliana MIHAI¹, Emilia BALINT², Nicolae MANOLESCU¹

¹The Romanian Academy, 125 Victoriei Avenue, District 1, postal code 010071, Bucharest, Romania, +4021 212 8284, E-mail: dr.iulia.mihai@gmail.com, manolescunicolae@yahoo.com

²The Faculty of Veterinary Medicine of Bucharest, 105 Independentei Street, District 5, postal code 050097, Bucharest, Romania, +4021.318.04.69, E-mail: emilia_balint@yahoo.com

Corresponding author email: dr.iulia.mihai@gmail.com

Abstract

The authors present a retrospective study on cases of malignant epithelial neoplasms in dogs and cats, over a period of time of two years (2013-2015), diagnosed in the Medical Clinic of the Faculty of Veterinary Medicine of Bucharest, within the cytology and hematology laboratory, with a quick and easy technique as the cytomorphological exam. In this paper work, based on the studied cases (39 dogs and 11 cats), we intend to bring new information related to the incidence of these cancer forms in the two species, analysing several aspects: solid tumors with various anatomical localizations (mammary gland, perianal region, testicle etc.), cellular proliferation of cavitory fluids and internal viscera solid tumors. Our study shows how of a great importance is to corroborate the clinical investigations with laboratory investigations. Our study demonstrated the possibility of double cancers or metastases, which are very important data for the therapy.

Key words: epithelial cancer, canine, feline, cytomorphology.

INTRODUCTION

Epithelial neoplasms are represented by the malignizations developed from the embryonic ectodermic foils, known as carcinomas (in the old nomenclature were known as epitheliomas) (Baba et al., 2007; Balint et al., 2005). However, epithelial malignancies have also some other specific names depending on location.

For knowledge, these neoplasms have been described and classified in the major chapters of malignant neoplasms in dogs and cats (Manolescu et al., 2009; Dinescu et al., 2013).

The literature in this field abounds in information about malignant epithelial neoplasms in dogs and cats, which shows very clearly that these are the most common forms of cancer found in these species (Baba et al., 2007; Balint et al., 2005; Cowell et al., 2008; Waldron, 2001; Withrow et al., 2007). Fact that we ascertained from all the cancer forms that we investigated in twenty years, for which we analysed this casuistry on global aspect, relying mainly on cytomorphological examination (Baker et al., 2000; Balint et al., 2013; Manolescu et al., 2009).

MATERIALS AND METHODS

Our study was conducted over a period of two years (November 2013 - November 2015) on a total of 50 cases (39 dogs and 11 cats) in the Medical Clinics of the Faculty of Veterinary Medicine of Bucharest.

The animals were included in our study after a clinical investigation, where tumor formations were put into evidence in various areas (mammary gland, perianal region, testicle etc.). As a result of laboratory tests and imaging (ultrasound, radiography), were detected cavitory fluids or tumors in the internal organs. The external solid tumors were diagnosed by biopsy puncture, from which smears and prints on microscope slides were performed, stained May-Grünwald Giemsa and microscopically examined using Olympus BX 51 optical microscope.

The intra-cavitory fluids were collected, and after centrifugation, from the obtained sediment, smears were performed, stained and examined in the same way.

A third category of casuistry was the one that presented tumor formations on the internal organs, that were visualized by ultrasound. In

these situations, after the necropsy, the tumoral formations were diagnosed by cytomorphological exams.

Another investigating method, for an important number of cases, was the nasal and gastric endoscopy.

With this method the presence and the aspects of the tumors were highlighted. Smears were

realized from the harvested tissue, stained May-Grünwald Giemsa and examined at the microscope.

RESULTS AND DISCUSSIONS

In tables 1 and 2 we present details on the cases included in the study.

Table 1. The incidence of malignant epithelial neoplasms in cats

No.	Sex	Age	Breed	Location	Citmorphological diagnosis
1.	Female	14 years old	European	Mammary gland	Anaplastic adenocarcinoma with vegetated areas
2.	Female	14 years old	European	Mammary gland	Vegetant adenocarcinoma
3.	Female	14 years old	Birman	Mammary gland	Solid adenocarcinoma
4.	Female	13 years old	European	Mammary gland	Papillary vegetant carcinoma
				Inguinal lymph node	Vegetant carcinoma metastasis
5.	Female	13 years old	Persian	Peritoneal cavity (fluid)	Cholangiocellular carcinoma metastasis
6.	Female	9 years old	European	Mammary gland	Vegetant adenocarcinoma
7.	Male	13 years old	Persian	Liver	Cholangiocarcinoma
8.	Male	12 years old	Birman	Lungs	Giant cell carcinoma
				Liver	Malignant hepatoma
				Tracheobronchial lymph node	Pulmonary giant cell carcinoma metastasis
9.	Male	11 years old	Birman	Pericardic cavity (fluid)	Mucosecretant carcinoma metastasis
10.	Male	4 years old	European	Auricular tegument	Carcinosarcoma
11.	Male	3 years old	European	Kidney	Dark cell carcinoma

Table 2. The incidence of malignant epithelial neoplasms in dogs

No.	Sex	Age	Breed	Location	Citmorphological diagnosis
1.	Female	16 years old	Mixed Breed	Mammary gland	Vegetant carcinoma
2.	Female	15 years old	Caniche	Mammary gland	Vegetant carcinoma
3.	Female	15 years old	Caniche	Pericardial cavity (fluid)	Vegetant carcinoma metastasis
4.	Female	14 years old	Mixed Breed	Supraorbital tegument	Vegetant carcinoma
5.	Female	14 years old	Mixed Breed	Mammary gland	Vegetant carcinoma
6.	Female	14 years old	Mixed Breed	Urinary bladder	Vegetant carcinoma with frequent giant cell forms
7.	Female	14 years old	Caniche	Mammary gland	Vegetant carcinoma
8.	Female	13 years old	Bichon	Mammary gland	Solid adenocarcinoma with vegetated high malignant areas
9.	Female	13 years old	Cocker Spaniel	Mammary gland	Vegetant adenocarcinoma
10.	Female	12 years old	German Shepard	Mammary gland	Papillary vegetant carcinoma with giant cell reaction
11.	Female	12 years old	Mixed Breed	Mammary gland	Canalicular vegetant adenocarcinoma
12.	Female	12 years old	Spitz	Mammary gland	Vegetant carcinoma
13.	Female	12 years old	Mixed Breed	Mammary gland	Vegetant carcinoma
14.	Female	11 years old	Bichon	Mammary gland	Vegetant adenocarcinoma with xanthomatous cellular elements
15.	Female	11 years old	Bichon	Mammary gland	Vegetant carcinoma
16.	Female	11 years old	Pekingese	Mammary gland	Papillary vegetant carcinoma

17.	Female	10 years old	Teckel	Mammary gland	Cancerous mastitis
18.	Female	10 years old	Husky	Peritoneal cavity (fluid)	Infected histiocitary mesothelioma
19.	Female	9 years old	Pinscher	Mammary gland	Adenocarcinoma
20.	Female	9 years old	Pekingese	Mammary gland	Papillary vegetant carcinoma
21.	Female	8 years old	Caniche	Cervical region (tegument)	Undifferentiated vegetant carcinoma
22.	Female	8 years old	Bulldog	Peritoneal cavity (fluid)	Epithelial-like mesothelioma
23.	Female	8 years old	Caucasian Shepard	Mammary gland	Vegetant adenocarcioma
24.	Female	7 years old	Mixed Breed	Nasal cavities	Estesiocarcinoma
25.	Female	7 years old	Mixed Breed	Nasal cavities	Vegetant carcinoma
26.	Female	7 years old	Golden Retriever	Nasal cavities	Estesiocarcinoma
27.	Female	7 years old	Cocker Spaniel	Mammary gland	Small cell vegetant carcinoma
28.	Female	5 years old	Terra Nova	Pleural cavity (fluid)	Massive carcinoma
29.	Female	5 years old	Mixed Breed	Phalanx	Squamos cell carcinoma
30.	Male	16 years old	Bichon	Prostate	Vegetant carcinoma
31.	Male	12 years old	Mixed Breed	Testicle	Seminoma
32.	Male	12 years old	German Shepard	Mammary gland	Vegetant carcinoma
				Testicle	Seminoma
33.	Male	10 years old	Mixed Breed	Testicle	Seminoma
34.	Male	10 years old	German Shepard	Urinary Bladder	Primary giant cell carcinoma
				Liver	Metastatic carcinomatous masses
				Lungs	Giant cell carcinoma metastasis
				Spleen	Giant cell carcinoma – individual metastatic elements
				Pleural cavity (fluid)	Giant cell carcinoma metastasis
				Intestine	Malignant lymphoma
35.	Male	9 years old	Airdale Terrier	Nasal cavities	Papilloma with high celullar activity
36.	Male	9 years old	Shih-Tzu	Stomach	Vegetant carcinoma
37.	Male	8 years old	Mixed Breed	Perianal region (tegument)	Undifferentiated carcinoma disseminated in the perianal tissue (fig. 2)
38.	Male	7 years old	Mixed Breed	Nasal cavities	Vegetant carcinoma
39.	Male	1 year old	Akita-Inu	Stomach	Malpighian carcinoma

Our studied casuistry conducted over a period of two years, diagnosed with various epithelial neoplasms was represented by: 11 cases in cats and 39 cases in dogs. The cat's age was between 3-14 years old, and for dogs: 1-16 years old.

The frequency of the solid external tumors in cats was represented by 6 cases, in which, 4 of them were located in the mammary gland, 1 with the same location but with an inguinal lymph node metastasis, and 1 in the auricular area.

In dogs the frequency of the solid external tumors was represented by 25 cases, in which 19 of them were located in the mammary gland and the other 6 of them had different locations as: 1 in the perianal area, 1 in the supraorbital tissue, 1 in the cervical area, 1 in the phalanx,

2 in the testicle) and 1 case with double location: in the mammary gland and in the testicle.

The frequency of the solid internal tumors in cats was represented by 3 cases: 1 with hepatic location, 1 with renal location and 1 with hepatic and pulmonary location. In dogs the presence of these neoplasms was identified in 11 cases: 5 cases in the nasal cavities, 1 in the urinary bladder, 1 in the prostate, 2 in the stomach, 1 in the intestine, 1 in the urinary bladder but with multiple metastasis located in the liver, lungs and spleen.

Another location, for the epithelial tumors within the two species (dogs and cats), was in the preformed cavities (peritoneal, pericardial, pleural), which in ultrasound examination presented fluid accumulations.

The incidence of these malignant forms of cancer was increased in dogs – 78% than in cats – 22%.

The incidence of these locations in cats was represented by 2 cases (18.18%): 1 case within the peritoneal cavity and 1 in the pericardial cavity, both representing the primary carcinoma metastasis.

In dogs were identified 5 cases: 2 within the pleural cavity with serous neoplasm (1 case with histiocytic mesothelioma (fig. 4) and 1 case with epithelial-like mesothelioma (fig. 5), 2 within the pleural cavity, both cases representing the primary carcinoma metastasis and 1 case within the pericardial cavity with metastatic cells from the primary tumor (10.25%).

From our investigated casuistry in cats (11 cases) we find that from the total number of epithelial cancers, the solid epithelial tumors located in the mammary gland were represented by a 45.45% percentage and 1 case with auricular location representing 9.09%.

The cats diagnosed with epithelial neoplasms in the internal organs represented 27.27% from the total of 11 animals. Also were diagnosed 2 cases with tumors in the preformed cavities, representing 18.18%.

From our casuistry in the canine specie, from the total of 39 dogs, 25 cases (64.10%) of solid external neoplasms were diagnosed, from which – mammary gland tumors: 19 cases, and 6 cases with different locations.

The neoplasms located in some internal organs and in the nasal cavities, totaled 10 cases (25.64%).

4 dogs were diagnosed with tumors in the preformed cavities, representing 10.25%, 2 of them presented epithelial carcinoma metastasis, and the other 2 were diagnosed with serous neoplasms (mesotheliomas).

The incidence of malignant epithelial neoplasms for the solid internal tumors, from the total number of 50 cases was represented by: in dogs, of 25.64% (10 cases from 30 animals); in cats, of 27.27% (3 cases from 11 animals).

This study highlighted the existence of some rare cancers in veterinary oncology. These are represented by double cancers encountered in the following cases:

- cats with pulmonary giant cell adenocarcinoma and malignant hepatoma;
- dog with urinary bladder giant cell carcinoma (fig. 1) and malignant lymphoma in the intestine;
- dog with mammary gland vegetant carcinoma and testicular seminoma. In this case we must specify that the mammary carcinoma was in a male dog, rare encountered fact in human and veterinary medicine.

Another important issue in the case of epithelial neoplasms found in the two species, is the appearance and development of metastasis. Their detection in the clinical investigation, laboratory and imaging is extremely necessary to contribute to the establishment of cancer therapy. In our casuistry we found the following variants:

- cat with vegetant carcinoma (fig.3) of the mammary gland with inguinal lymphnode metastasis;
- cat with double cancer (lungs and liver) with pulmonary carcinoma and tracheobronchial lymph node metastasis;
- cat with mucosecretant carcinoma metastasis in the pericardial fluid;
- dog with double cancer (urinary bladder, intestine): presented numerous giant cell carcinomatous metastatic masses in the liver, lungs and spleen;
- dog with vegetant carcinoma metastasis in the pericardial fluid;
- dog with massive carcinoma metastasis in the pleural fluid.

The incidence of epithelial neoplasms in dogs and cats is represented by a large variety of locations and cellular forms.

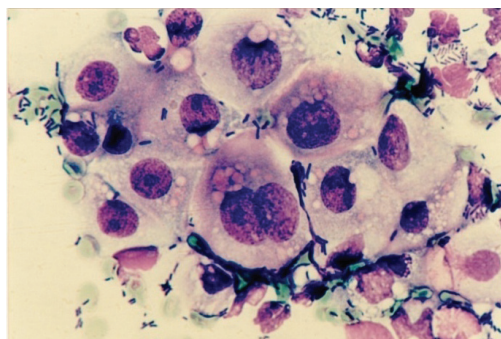


Fig. 1 – Vegetant adenocarcinoma (urinary bladder from a dog) – MGG x 1000

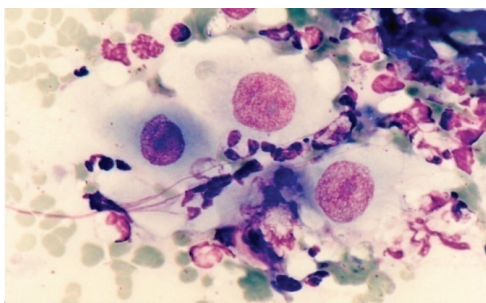


Fig. 2 – Undifferentiated carcinoma (neoplasm of the perianal tissue from a dog) – MGG x 1000

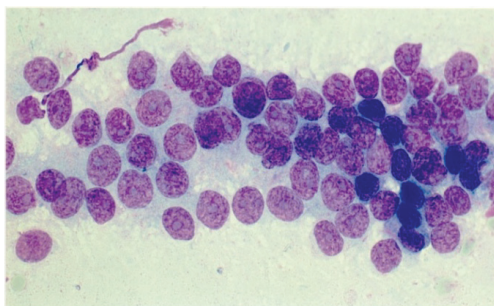


Fig. 3 – Vegetant carcinoma (mammary neoplasm from a cat) - MGGx1000

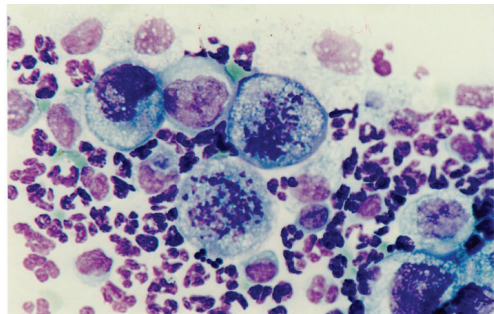


Fig. 4 – Histiocytic-like mesothelioma from a dog - MGGx1000

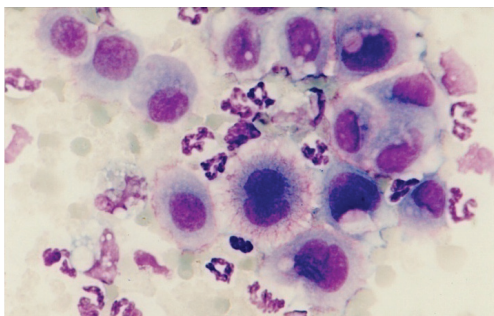


Fig. 5 – Epithelial-like mesothelioma from a dog - MGGx1000

CONCLUSIONS

1. The value of diagnose based on the cytomorphological exam is given by the speed with which is done and the high-fidelity obtained images.
2. The incidence of epithelial malignant neoplasms in the canine specie is much greater than the cases found in cats.
3. Mammary gland carcinomas are the most common, found in both species, compared to other tumor locations.
4. Corroboration of clinical investigations with laboratory and imaging is important to detect some double cancers and the metastasis; these data are helping the veterinary practitioner to conduct a better therapy.

REFERENCES

- Baba A.I, Cătoi C., 2007. Comparative Oncology, The Publishing House of the Roumanian Academy, Bucharest.
- Baker Rebecca., Lumsden J.H., 2000. Color Atlas of Citology of the cat and a dog, Mosby Inc
- Balint Emilia, Manolescu N., 2005. The importance of cytodiagnosis in comparative oncology, HealthWorlds Asia, Singapore, 11-13 Nov., Poster Abstracts, 27.
- Balint Emilia, N. Manolescu, D. Lastofka, 2013. Peculiar aspects regarding the synchronous evolution of two cancers (double cancer) in canine and feline. Lucrari Stiintifice – Universitatea de Stiinte Agricole a Banatului Timisoara, Medicina Veterinara, Vol. 46, No.1, pp. 5-8.
- Christopher D.M., 2007. Fletcher, "Diagnostic histopathology of tumors".vol.1, Churchill Livingstone Elsevier.
- Cowell L.R., Tyler R.D., Meinkoth J.H., DeNicola D.B., 2008. Diagnostic cytology and hematology of the dog and cat, Mosby Elsevier.
- Dinescu Georgeta, Băjenaru Daniela, Soare T., 2013. Nasal anaplastic carcinoma – case report. Scientific Works. Series C. Veterinary Medicine. Vol. LIX (2) , pg. 204.
- Manolescu N., Balint Emilia, 2009. Atlas of canine and feline onchocytomorphology, Curtea Veche Publishing, Bucharest.
- Waldron D.R: 2001. Diagnosis and surgical management of mammary neoplasia in dogs and cats. Vet Med 96: 943-948.
- Withrow S.J., 2007. Gastric Cancer. In: Withrow and MacEwen's Small Animal Clinical Oncology. Withrow SJ and Vail DJ, eds. Saunders Elsevier, St. Louis, pp 480-483.4.