

## COMPARATIVE THERAPEUTIC APPROACH OF CANINE TRANSMISSIBLE VENEREAL TUMORS (TVT)

B. Al. Vițălaru<sup>1</sup>, D. Crânganu<sup>1</sup>, G. Polter<sup>2</sup>

1–Faculty of Veterinary Medicine Bucharest, Romania, [alexandrumv@yahoo.com](mailto:alexandrumv@yahoo.com);  
2 - North Downs Specialist Referrals, United Kingdom

### Abstract

**Introduction:** In Romania, monochemotherapy using exclusively Vinca Rosea alkaloids created mutant cellular clones of Sticker sarcoma, activating MDR severe mutant genes.

**Materials and Methods:** During this study, a number of 10 dogs with TVT, of different breeds, genders and ages have been studied. Blood tests, X-Rays, coagulation profile, biochemistry of the blood, urine dipstick, abdominal ultrasound and cytology - FNA from the biopsy mass were performed. All the submitted samples were analyzed in reference laboratories from both Romania and Netherlands. The history, clinical and histological findings were all compatible with TVT. The approach was different in the two Clinics. In UK, the therapeutic approach was different, using Vincristine 0,7mg/m<sup>2</sup> week one, repeated every 7 days three more times. In Romania, monochemotherapy created mutant cellular clones of Sticker sarcoma. Therefore, polychemotherapy has been used (genital localization, expansive and proliferate pattern with no metastases). Preoperative, neoadjuvant polychemotherapy for cytoreduction, based on cyclophosphamide 50mg/m<sup>2</sup> or ifosfamide 200mg/m<sup>2</sup>, cyclo dependent cytostatics, and 5-fluorouracil as an antimetabolite, 50mg/m<sup>2</sup> and Vincristine 0,7mg/m<sup>2</sup> week one, repeated every 14 days or after surgery to prevent recurrence.

**Results:** All cases treated in UK with Vincristine and all Romanian dogs treated with polychemotherapy shown remission of the penile masses and complete healing. In Romania, monochemotherapy created mutant cellular clones.

**Conclusion:** Numerous cases of TVT in the free dog population in Romania and uncontrolled breeding, along with the absence of neutering (castration) favored the spread of tumors and the transmission of resistance from one dog to another.

**Key words:** canine, polychemotherapy, Sticker, transmissible, TVT.

### INTRODUCTION

Transmissible venereal tumor (TVT) still bears the name of infectious sarcoma venereal granuloma, transmissible lymphosarcoma or Sticker tumor (Hasler and Weber, 2000).

TVT is a reticuloendothelial tumor of the dog, which is usually localized at genitalia, occasionally at the level of internal organs (Morrison, W.B., 1998).

It is a contagious cancer that is transmitted along with viable cells and fails to cross the barriers of the major histocompatibility complex between dogs and between family members in the Canidae family such as foxes, coyotes and jackals (Martins et al, 2005, Mukaratirwa and Gruys, 2003).

TVT was first described by Novinsky in 1876, which showed that the tumor could be transplanted from one susceptible host to another by inoculation of tumor cells (Rebeck et al, 2009). The transmissible agent causing canine transmissible venereal tumor (CTVT) is thought to be the tumor cell itself (Murgia et al, 2006).

Numerous cases of TVT in the free dog populations of Romania have favored the spread of tumors and transmission of chemotherapy resistance from one dog to another. It usually responds very well to polychemotherapy, although there are areas with small populations which show satisfactory results to monochemotherapy (Rogers et al 1998).

## **MATERIALS AND METHODS**

During this study, a number of 10 dogs with TVT, from different breeds, genders and ages have been studied. (Figures 1-4)

Blood tests, X-Rays, coagulation profile, biochemistry of the blood, urine dipstick, abdominal ultrasound and cytology - FNA from the biopsy mass were performed. All the submitted samples were analyzed in reference laboratories from both Romania and Netherlands. The history, clinical and histological findings were all compatible with TVT.

The approach was different in the two Clinics. In UK, the therapeutic approach was different, using Vincristine  $0,7\text{mg}/\text{m}^2$  week one, repeated every 7 days for three more times. In Romania, at the Faculty of Veterinary Medicine in Bucharest, it was observed that monochemotherapy based exclusively on the Vinca Rosea alkaloids, among which the most widely used are Vincristine and Vinblastine, created mutant forms of Sticker's sarcoma cell clones with MDR gene activation (multidrug resistance) and serious side effects on the treated animal. Therefore, polychemotherapy has been used (genital localization, expansive and proliferate pattern with no metastases). Preoperative, neoadjuvant polychemotherapy for cytoreduction has been used based on cyclophosphamide  $50\text{mg}/\text{m}^2$  or ifosfamide  $200\text{mg}/\text{m}^2$ , cyclo dependent cytostatics, and 5-fluorouracil as an antimetabolite,  $50\text{mg}/\text{m}^2$  and Vincristine  $0.7\text{mg}/\text{m}^2$  week one, repeated every 14 days or after surgery to prevent recurrence. A batch of Vincristine  $0.7\text{mg}/\text{m}^2$  treated dogs using 3 doses in 7 days was created. (Table 1)

Table 1. The two treatment protocols in the Faculty of Veterinary Medicine Bucharest and North Downs Specialist Referrals

CLINIC	NUMBER OF CASES	TREATMENTS	TREATMENT LENGHT
Faculty of Veterinary Medicine Bucharest	4	<i>Cyclophosphamide 50 mg/m<sup>2</sup> or Ifosfamide 200 mg/m<sup>2</sup>, and 5-Fluorouracil, 50 mg/m<sup>2</sup></i>	At 14 days, alternating 3 treatments
	3	<i>Vincristine 0,7 mg/m<sup>2</sup></i>	3 treatments at every 14 days
North Downs Specialist Referrals	3	<i>Vincristine 0,7 mg/m<sup>2</sup></i>	4 treatments at every 7 days

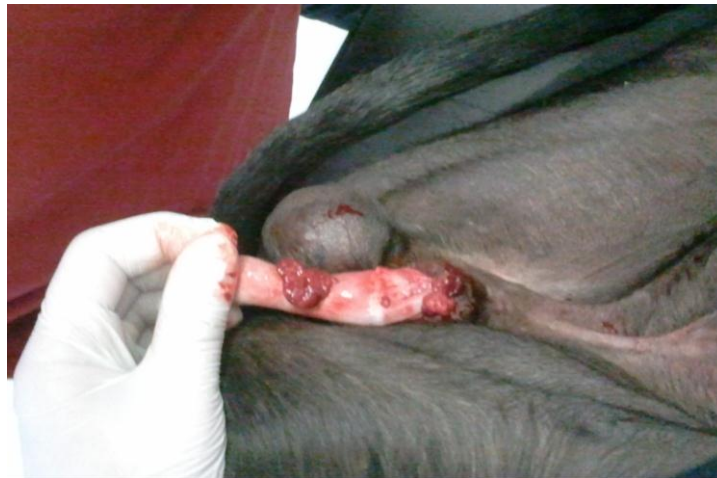

Figure 1. Sticker tumor at a 5 years old English Greyhound male (orig.)

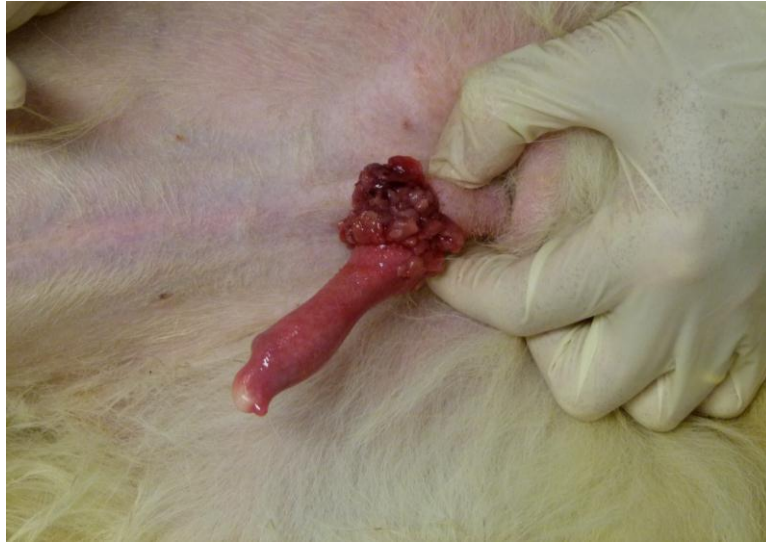

Figure 2. Sticker tumor at a 10 years old Samoyed male (orig.)

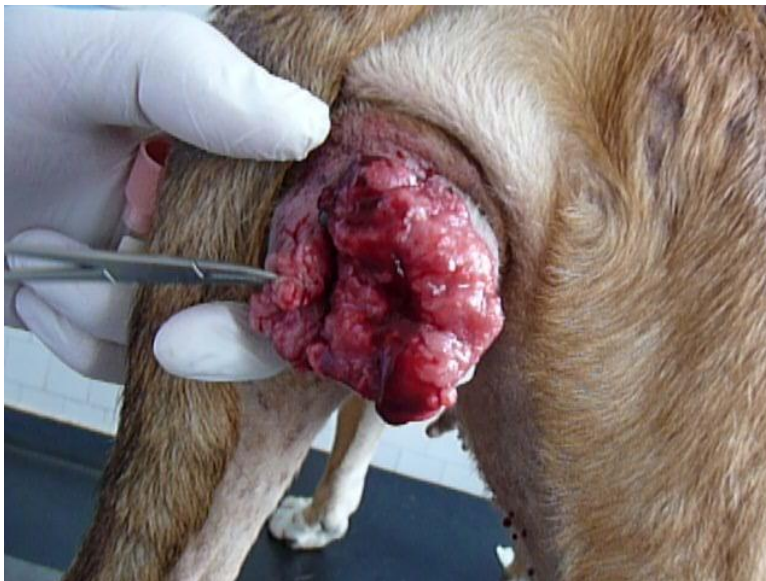


Figure 3. Sticker tumor at a 7 years old Amstaff female (orig.)

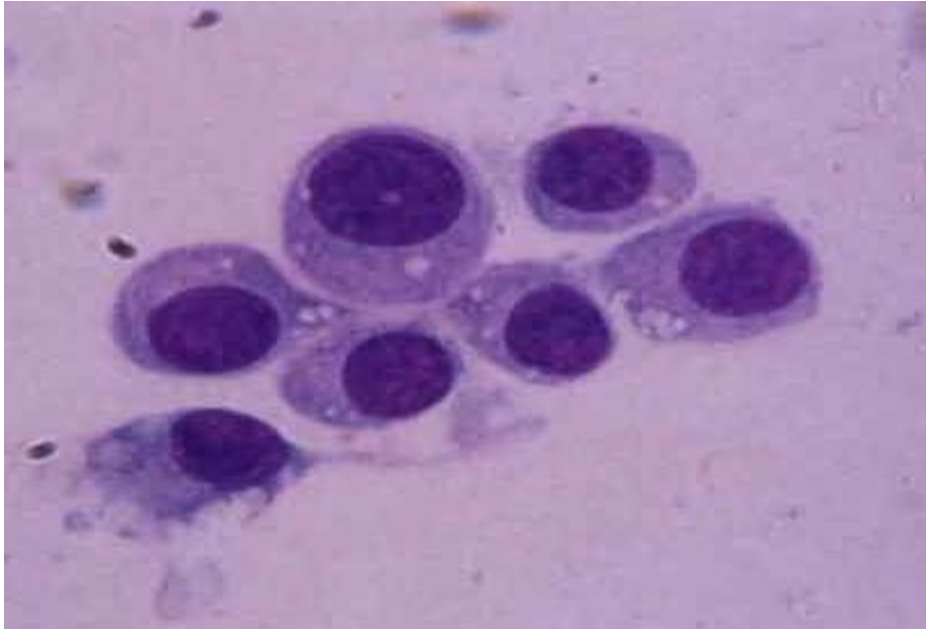

Figure 4. TVT round or slightly polyedric cells, with thin cytoplasm in which vacuoles and a round, hyperchromic nucleus with a single nucleolus and a low number of mitotic elements are visible (orig.)

## RESULTS AND DISCUSSIONS

In Romania, monochemotherapy based solely on Rosea Vinca alkaloids created mutant cell clones and produced incomplete healing and recovery with local or general metastasis. All cases in our study treated unilateral with Vincristine, generated returns.

All cases treated in the UK, with Vincristine ended in complete remission and healing masses.

Out of the 4 cases in Romania treated using preoperative neoadjuvant multi-agent cytostatic, a total of three cases (75%) were completely cured and had no recurrences. (Figures 5, 6)

Table 2. The two treatment outcomes using the protocols in the Faculty of Veterinary Medicine Bucharest and North Downs Specialist Referrals

CLINIC	NUMBER OF CASES	TREATMENTS	TREATMENT OUTCOME
Faculty of Veterinary Medicine Bucharest	4	<i>Cyclophosphamide 50 mg/m<sup>2</sup> or Ifosfamide 200 mg/m<sup>2</sup>, and 5-Fluorouracil, 50 mg/m<sup>2</sup></i>	Completely healed (3, 75%)
	3	<i>Vincristine 0,7 mg/m<sup>2</sup></i>	Incomplete healing or recurrence (3, 100%)
North Downs Specialist Referrals	3	<i>Vincristine 0,7 mg/m<sup>2</sup></i>	Completely healed (3, 100%)




Figure 5. Sticker tumor remission at a 10 years old Samoyed male after treatment using polychemotherapy (orig.)

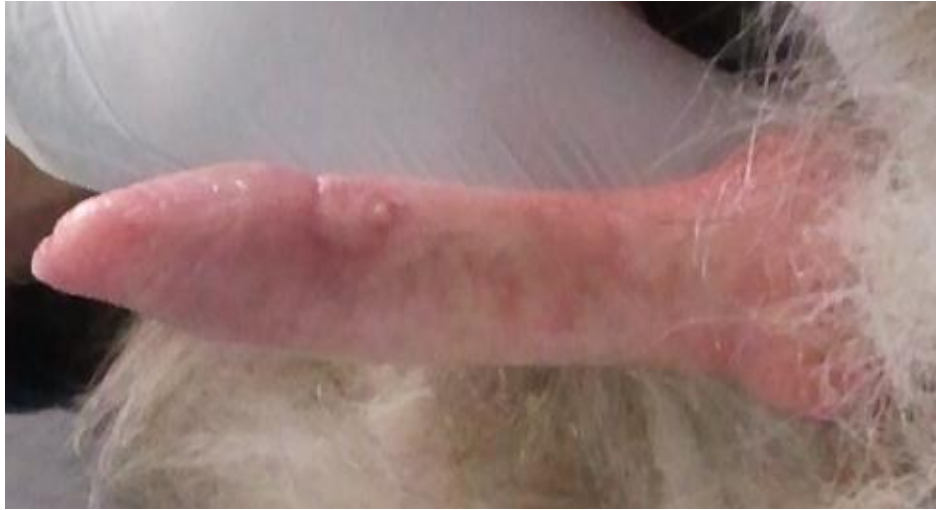

Figure 6. Sticker tumor remission at a 10 years old Samoyed male after treatment using polychemotherapy - detail (orig.)

## **CONCLUSIONS**

Numerous cases of TVT in Romanian free dog populations and uncontrolled breeding, along with monochemotherapy based solely on Vinca rosea alkaloids, among which the most widely used are Vincristine and Vinblastine, created mutant forms of Sticker's sarcoma cell clones with MDR gene activation (multidrug resistance) and serious side effects on the treated animal.

Lack of castration favored tumor spread and resistance transmission from one dog to another.

Vinca alkaloids intervene in the S phase of the cell cycle blocking the specific mitotic division spindle of normal eukaryotic cells. Cancer cells do not have spindle of division, multiplying exclusively by amitotic direct division, thus having no Vincristine or Vinblastine sensitivity. Thus, Vincristine alone cannot be considered a cure for TVT.

## **ACKNOWLEDGEMENTS**

The author would like to thank to the staff from North Downs Specialist Referrals for collecting the data and providing it in a very short time.



## REFERENCES

- Hasler A, Weber W., 2000. "Theriogenology question of the month. Transmissible venereal tumor (TVT)". *J. Am. Vet. Med. Assoc.* 216 (10): 1557–9. PMID 10825939.
- Martins M., De Souza M.I., Ferreira F., Gobello C., 2005. "Canine transmissible venereal tumor: Etiology, pathology, diagnosis and treatment". *Recent Advances in Small Animal Reproduction*. Retrieved 2006-05-25.
- Morrison, W.B., 1998. *Cancer in Dogs and Cats* (1st ed.). Williams and Wilkins. ISBN 0-683-06105-4.
- Mukaratirwa S., Gruys E., 2003. "Canine transmissible venereal tumour: cytogenetic origin, immunophenotype, and immunobiology. A review". *The Veterinary quarterly* 25 (3): 101–11.
- Murgia, C., Pritchard J.K., Kim S.Y., Fassati A., Weiss R.A., 2006. "Clonal Origin and Evolution of a Transmissible Cancer". *Cell* 126 (3). [//www.ncbi.nlm.nih.gov/pmc/articles/PMC2593932/](http://www.ncbi.nlm.nih.gov/pmc/articles/PMC2593932/).
- Rebbeck CA, Thomas R, Breen M, Leroi AM, Burt A., 2009. "Origins and Evolution of a Transmissible Cancer". *Evolution* 63 (9): 2340–2349.
- Rogers K., Walker M., Dillon H., 1998. "Transmissible venereal tumor: a retrospective study of 29 cases". *Journal of the American Animal Hospital Association* 34 (6): 463–70.