

**STUDY OF THE AXIAL SKELETON IN THE GIRAFFE
(GIRAFFA CAMELOPARDIS)
COMPARED TO ITS BOVINE COUNTERPART**

A. Damian, Al. Gudea, Alexandra Blendea, I. Ciama, F. Tuns, Irina Irimescu

*Faculty of Veterinary Medicine, USAMV Cluj-Napoca,
Calea Mănăştur nr. 3-5, Cluj-Napoca, Romania, catedra1mv@yahoo.com*

Abstract

*The giraffe (*Giraffa camelopardis*) is known as the tallest land mammal of African origins. Its unique evolution has led to the development of singular morphological features. Its rare presence outside its natal continent makes the giraffe a rarely studied species in our country, which makes any new research regarding this species a valuable addition to our anatomic database. **Materials and Methods:** The study was performed in the Comparative Anatomy Laboratory of the Faculty of Veterinary Medicine of Cluj-Napoca. One giraffe body and two cow skeletons were used to determine the anatomical differences between the thoracic, lumbar sacral and coccygeal segments of the vertebral column, the ribs and the sternum in these two species. The body was processed through usual techniques maintaining the thoracic skeleton intact due to the individual's young age. The cow skeletons belong to our ossuary collection. We have chosen to compare the giraffe to the cow, because this is the reference ruminant for veterinary anatomy, well studied both in our country and on an international level. **Results and Conclusion:** The main differences, underlining biomechanical consequences, were registered in the thoracic, lumbar, sacral segments and in the sternum. The giraffe has an extra thoracic vertebra and an extra pair of ribs, but it has a smaller thoracic length ratio to the total body length. The lumbar and sacral segments each lack a vertebra. The sternum is narrow. The dorsal profile of the trunk has a more pronounced decline in height from the withers to the lumbar segment, and its general shape is dorso-ventrally narrowed to its extremities, making it more compact than in bovines.*

Key words: giraffe, cow, trunk, skeleton, anatomy.

INTRODUCTION

The giraffe is rarely studied outside its natal continent, Africa, as it is found only in zoological parks and certain circuses. This research adds to the reduced osteology database currently available on this species, by comparing its trunk skeleton, along with the coccygeal segment to the main reference domestic ruminant species, the cow, and underlines its particular features.

The giraffe (*Giraffa camelopardalis*) is a species of the *Giraffidae* family, along with only one other living species, the okapi. In the prehistoric period, this family contained a great number of *genera*. Stevens (1993), states that the early giraffes resembled the prehistoric antelopes from Europe and Asia, 30-50 million of years ago, and have progressed since then from one meter to three meters in height. The early Miocene presented a stag-like giraffid, the *Climacoceras*, and forward to the middle of the Miocene there two genera, *Palaeotragus* and *Samotherium*, an increased withers height and developed ossicones, similar to today's giraffe, but with still shorter necks. At end of Pliocene, a drastic reduction of the giraffids took place, ending in only two remaining species (Prothero and Schoch, 2003). The remaining genus *Giraffa*, survivor from the Pliocene, contained a list of long-necked species, like the *Jumae giraffa*, some of which did not propagate to the modern era (Savage and Long, 1986). The modern giraffe is the tallest land animal mostly due to its extremely long neck, which can represent half of its total height (Henderson and Naish, 2010), but it also has a great wither height.

MATERIALS AND METHODS

The research was carried out in the Comparative Anatomy Laboratory of the Faculty of Cluj-Napoca, using one giraffe body donated by a circus transiting through Cluj-Napoca and two bovine skeletons belonging to the ossuary of our department. The trunk segment of the giraffe body was obtained using common techniques adapted for the age group of the individual who was under one year old, and had not reached adult development.

Due to the fragility shown by the cervical segment during thermal processing, we have opted to maintain the joints between the thoracic vertebrae, the ribs and the sternum, obtaining a single thoracic piece. After preserving the various body segments at -18°C, the thorax was de-frozen, and its gross soft tissues were removed of the vertebrae, the ribs and the sternum. The piece was then kept in a 10% formaldehyde solution for 4 days, and underwent a second mechanical cleaning. Finally it was hung to dry in a constant temperature environment.

The lumbar and sacral segments were thermically processed using detergent and whitening solutions, at lower temperatures than usually used for adult skeletons.

After obtaining the giraffe osseous pieces, we have macroscopically examined the distinctive surface features of the thoracic, lumbar, sacral and coccygeal vertebrae, of the ribs and of the sternum, in the two examined species.

RESULTS AND DISCUSSIONS

In cows, there are 13 thoracic vertebrae with short well-developed bodies, with a strong ventral ridge. Their transverse processes are present, smaller than in horses, and the articular processes are reduced and flat (Fig.1A). Except for the last thoracic vertebra, the intervertebral foramina go through the caudal edge of the laminae of the vertebral arch. The spinous processes are thick on their entire length and end with tuberosities. They reach the maximum height in the T2-T5 vertebrae (Fig.1B). Starting from the 5th vertebra, the spinous process decreases up to the 10th vertebra. The spinal processes have a pronounced dorso-caudal orientation (caudoversion) up to T12, which is vertical, and the last vertebra (T13) may have a dorso-cranial orientation (cranioversion) (Barone, R., 1966; Damian, A., *et al.*, 2001).



Fig.1. A - T7 in the cow, cranial view; B - Vertebral column of the cow, lateral view.

The giraffe presents an extra vertebra, having a total of 14 thoracic vertebrae (Fig.2B). Due to maintaining the thorax piece intact, this segment was examined only for gross characteristics, without being able to visualize the details. However, we have been able to assess the main differences between species. The vertebrae body is shorter and finer in the giraffe, and the ventral ridge is not prominent (Fig. 2A). The transverse processes, like the cow's are poorly developed (Fig.45). The spinous processes in the giraffe are narrower than those of the cow, but their width is constant along their length. Their height increases suddenly from the T1 to T2, reaches a

maximum at T2 - T4, then it decreases more than in bovines up to the lumbar segment. The first spinal processes are almost vertical, the T4 - T7 segment presents a slight caudoversion, which disappears at the last vertebrae, which are vertical, lacking the cranioversion displayed by cows.

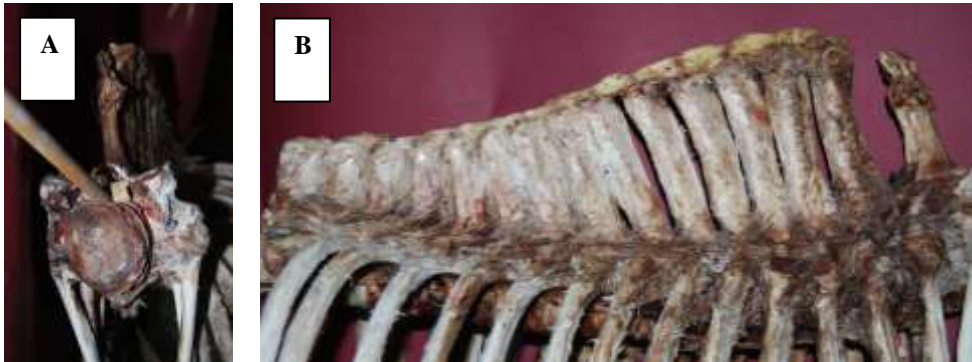

Fig.2. A - T1 in the giraffe, cranial view; B - vertebral column of the giraffe, lateral view.

Bovines have 6 lumbar vertebrae with long and massive bodies, narrow ventral ridges and short but broad spinal processes, decreasing in height from the first to the last (Coțofan, V., *et al*, 1999). The transverse processes are long, narrow and slightly bent forward, having a general aspect of „heron wings” (Fig.3A). Their length increases up to L5, while L6 is equal to L3 (Barone, R., 1966). The mammillary processes are united with the cranial articular surfaces, well developed and form together a particular aspect of „buffalo horns” (Damian, A., *et al.*, 2001).

The giraffe specimen has only 5 lumbar vertebrae (Fig.3B), denoting a shorter lumbar region in this species. These have well developed bodies, but they are shorter than in bovines, with reduced ventral ridges. The spinous processes are short but well developed, ending with tuberosities, decreasing slowly from L1 to L5, and bending slightly caudally. The transverse processes are less developed in the giraffe, still decreasing from L1 to L4, with narrow bodies, leaving large spaces between them. Their edges are smoother than in cows and a lot less convex, missing the “heron wings” resemblance. The mammillary processes are united with the cranial articular processes, but the “buffalo horns” aspect is much reduced.

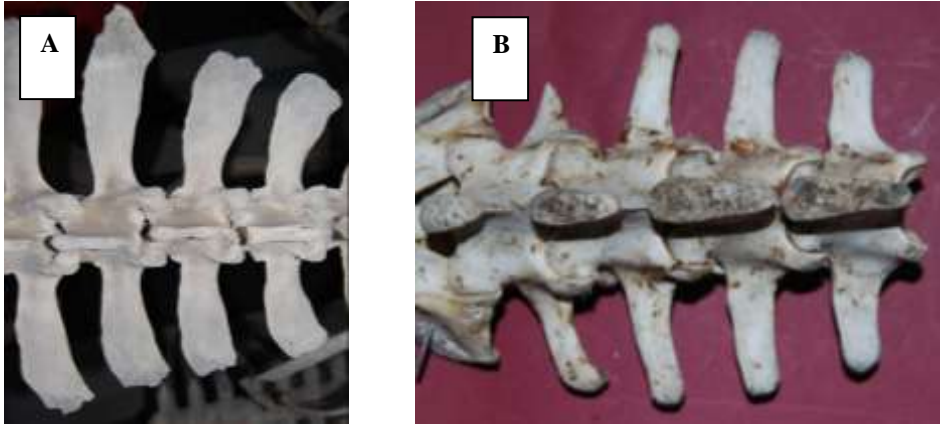


Fig.3. Lumbar segment in the cow (A) and in the giraffe (B), dorsal view.

The sacral vertebrae are united forming the sacrum. The cow presents 5 sacral vertebrae with flattened bodies. The spinous processes are completely fused, forming a median sacral crest (Coțofan, V., *et al.*, 1999) with a rough edge. The 4 superior sacral foramina are partially covered by a well developed mammillary ridge, except for the last one which is very large. The articular head is flat, and the first cranial articular processes retain the “buffalo horns” aspect from the lumbar segment. The lateral edges, former transverse processes, are slim, sharp, slightly curved ventrally and rapidly decrease in size from the first element (the sacral wings) to the last. The cranial opening of the sacral canal is shaped like a dorso-ventrally lattened triangle. The ventral side of the sacrum is concave cranio-caudally (Fig.4A)(Barone, R., 1966; Damian, A., *et al.*, 2001).

The giraffe has an even smaller sacrum, with only 4 vertebrae (Fig.4B). These have well developed bodies, but, due to the age of the animal they are not fused. The spinous processes are proportionally larger than in the cow, but narrower, ending with well developed tubercles. The mammillary crests are poorly developed, incompletely fused and do not cover the 3 supra sacral foramina. Both supra and sub sacral foramina have a uniform diameter, lacking the obvious variations found in bovines (Fig.4A,B). The transverse processes are smaller than in bovines, with thick rounded edges. The articular head is flat, but the cranial articular processes are simple, lacking the “buffalo horns” aspect. The cranial opening of the sacral canal is shaped like a equilateral triangle. The ventral side has a more pronounced concave profile than in cows.

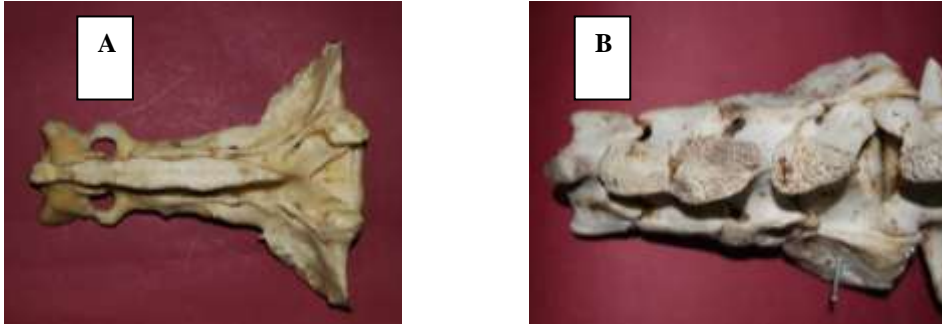


Fig.4. Sacral segment in the cow (A) and in the giraffe (B), dorsal view.

The cow has a well developed tail, containing 18 to 21 vertebrae (Barone, R., 1966; Vasile Coțofan et al., 1999). These coccygeal vertebrae lose their neural arch starting with the 4th one, and the other elements from the 10th one to the last. The first coccygeal segments present a ventral hemal arch.

The giraffe has a proportionally shorter tail, compared to its body size, than the cow. The studied specimen presents 18 coccygeal vertebrae. Their bodies are longer and smoother than in bovines, losing their surface elements in the same fashion (Fig.5A,B).

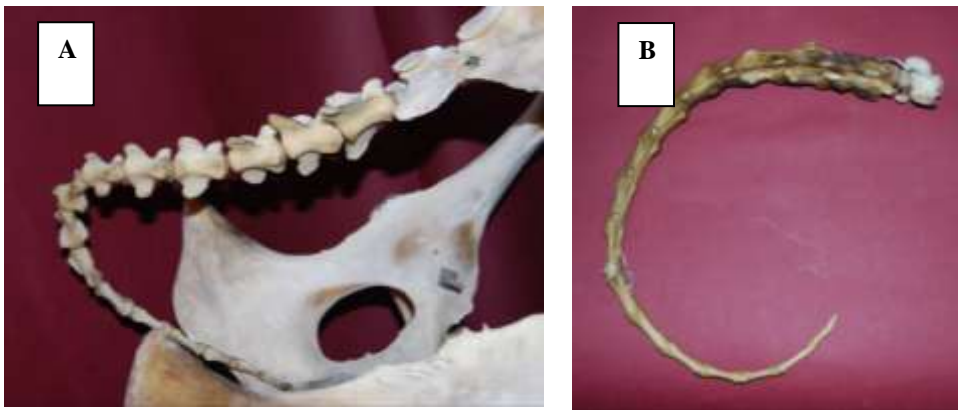


Fig.5. Coccygeal segment in the cow (A) and in the giraffe (B), lateral view.

The cow has 13 pairs of ribs, of which 8 are sternal and 5 floating. They are long, not very arched, with little mobility (Fig.6A). Their inferior segment is very broad with sharp and thin edges. Their neck is long and their articular

head, well developed (Barone, R., 1966).

The giraffe has 14 pairs of ribs, showing an extra pair of floating ribs. They are not excessively arched, narrower than those of the cow, with rounded edges (Fig.6B) Just like in bovines, the osseous segments of the ribs do not present only a slight ventro-caudal tilt. The costal cartilages are longer and more cylindrical than those of the cow, and the hyocondrum is finer.

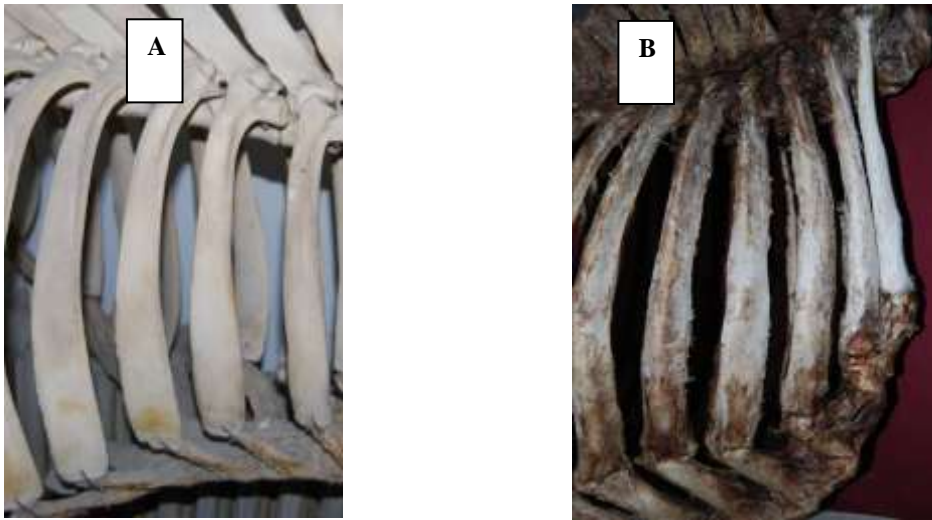


Fig.6. Ribs in the cow (A) and in the giraffe (B), lateral view.

The sternum is an osteo-cartilaginous piece in mammals, placed on the ventro-medial plane, representing the floor of the thorax, composed of sternbrae and articular surfaces for the cartilaginous segments of the sternal ribs (Damian, A, 2001).

The cow's sternum presents 7 sternbrae and has a dorso-ventrally flattened body, narrowed at both extremities and a lot wider cranially (Fig.7A). It offers articular surfaces for eight pairs of ribs. The manubrium is massive and pyramidal, perpendicular on the second sternbrae. There is not marked sternal keel. Consecutive sternbrae are growing larger except the last two. The surfaces of the condro-costal articulations are well defined. The sternum ends in a round small xiphoid process (Barone, R., 1966).

The giraffe's sternum is also composed of 7 sternbrae (Fig.7B), but its general shape shows important differences. The sternbral body is strongly narrowed in the first elements, and the width of the last ones is also much reduced compared to the cow's. The sternal keel is prominent on the ventral face of the sternbrae, with a curved profile, and a marked concavity of the

dorsal face. The manubrium is very narrow and the xiphoid couldn't be examined, as it was detached during the processing of the thoracic piece.




Fig.7. Sternum of the cow (A) and of the giraffe (B), caudal view.

As previously mentioned the ribs together with the thoracic vertebrae and with the sternum create a protective space for the internal organs of the thoracic cavity.

In the cow, due to the displacement of the thoracic legs in an almost exclusively parasagittal plane, the thorax is flattened latero-laterally (Fig.8A) (Barone, R. 1966). The line traced by the spinal processes is almost horizontal in bovines, without a slope following the withers. The profile of the thorax skeleton is elongated, with straight angles cranially, which confers it a rectangle aspect. Caudally, the thoracic cavity gains in volume.

In the giraffe, the thoracic cavity, although massive and endowed with an extra pair of ribs, has a shorter longitudinal axis, related to the general body measurements, than in the cow (Fig. 8A). The line of the back is inclined, the spinal processes marking a sudden decrease in height after the peak reached by the withers, which continues to the lumbar segment. The thorax of this species is flattened not only latero-laterally, but also narrowed dorso-ventrally at its extremities.




Fig.8. Dorsal view of the thoracic cavity in the cow (A) and in the giraffe (B).

CONCLUSIONS

The thoracic vertebrae are 14, with an even width on the spinal processes, smaller than in the cow; their height rapidly increases from T1 to T2, reaches the maximum in between T2 and T4, after which it decreases to the lumbar segment.

The lumbar vertebrae are 5, with well developed, but short bodies, short spinal processes, slightly inclined caudo-dorsally; less developed transverse processes, linear with rounded ends.

The sacrum contains 4 vertebrae incompletely merged, smaller than in the cow, with higher but narrower spinous processes. There are 3 superior and inferior sacral foramina. The articular surfaces for the pelvis are situated on the latero-dorsal side of the wings of the sacrum.

The coccygeal vertebrae are 18 with long and fine bodies, showing less developed surface elements than the bovines.

The giraffe displays 14 pairs of **ribs**, 8 sternal and 6 floating, with a smaller width than in the cow.

The sternum contains 7 sternbrae, which bodies are strongly narrowed in the first elements, and smaller than in the cow in the last elements. The sternal keel is well marked on the ventral side, and the profile is curved

The thoracic cavity in the giraffe is massive endowed with an extra pair of ribs. It has a shorter longitudinal axis reported to the general body measurements, than in the cow.

Due to the ventro-cranial inclination angle of the thoracic vertebral spine and to the convexity of the sternum, the thorax of the giraffe is narrowed in both extremities.

REFERENCES

- Barone, R. (1966). Anatomie comparée des mammifères domestiques. Laboratoire d'anatomie. Ecole Nationale Veterinaire Lyon.
- Coțofan, V., R. Palicica, V. Hrițcu and V. Enciu (1999). Anatomia animalelor domestice, vol.I - Sistemul de susținere și mișcare. Ed. Orizonturi Universitare, Timișoara.
- Damian, A., N. Popovici and I. Chirilean (2001). Anatomie comparată: sistemul de susținere și mișcare. Ed. AcademicPress, Cluj-Napoca.
- Henderson, D.M. and D. Naish (2010). Predicting the buoyancy, equilibrium and potential swimming ability of giraffes by computational analysis. *J. Theor. Biol.* 265(2):151-9.
- Paștea, E., Gh. Constantinescu, E. Mureșan and V. Coțofan (1978). Anatomia comparată și topografică a animalelor domestice. Ed. Didactică și Pedagogică, București.
- Pratt, D.M., and V.H. Anderson (1985). Giraffe social behaviour. *Journal of Natural History.* 19:771-782.
- Prothero, D.R. and R.M. Schoch (2003). *Horns, Tusks and Flippers: The evolution of Hoofed Mammals.* The Johns Hopkins University Press.
- Savage, R.J.G. and M.R. Long. (1986). *Mammal evolution: an illustrated guide.* New York, Facts on File. 228-229.
- Simmons, R.E. and R. Altwegg (2010). Necks-for-sex or competing browsers? A critique of ideas on the evolution of giraffe. *Journal of Zoology.* 282:6-12.
- Stevens, J. (1993). Familiar Strangers. *International Wildlife.* 23,6-10.