

IN VIVO EFFECTS OF TITANIUM IMPLANTS TREATED WITH BIOMATERIALS IN THE BONE REGENERATION PROCESS

**Diana-Larisa ANCUȚA^{1,2}, Maria CRIVINEANU²,
Teodoru SOARE², Cristin COMAN^{1,3,4}**

¹“Cantacuzino” National Medico-Military Institute for Research and Development, Splaiul Independenței 103, Bucharest, Romania

²University of Agronomic Sciences and Veterinary Medicine, Faculty of Veterinary Medicine, Splaiul Independenței 105, Bucharest, Romania

³Fundeni Clinical Institute, Center of Excellence in Translational Medicine, Fundeni Road 258, Bucharest, Romania

⁴“Spiru Haret” University, Faculty of Veterinary Medicine, Basarabia Boulevard, Bucharest, Romania

Corresponding author e-mail: diana.larisa.ancuta@gmail.com

Abstract

The biological interface between the host tissue and the medical device used may influence clinical outcomes. Expected effects include osteoinduction, osseointegration, increased vascularity, and mechanical stability. The aim of the study was to evaluate the process of bone regeneration and potential local effects as results of insert implants treated with innovative biomaterials in the intercondylar rat femur. Two groups of rats, Wistar, were created to which titanium implants were applied to the femoral bone. In one of the groups, the titanium implant coated with Poly (3-hydroxybutyric acid-3-hydroxyvaleric acid) polymer microspheres enriched with fibroblast growth factor 2, vascular endothelial growth factor and bone morphogenetic protein 4 (VGF2) was inserted and in the other group, the implant was untreated. After 6 weeks of clinical monitoring, rats were euthanized, and the implanted femur was harvested for histological analysis. In this study the data obtained showed that VGF2-treated implants contributed to faster bone regeneration, with favorable local effects, compared to untreated implants in which signs of persistent inflammation were.

Key words: animal model, implant, osteoinduction, osseointegration.

INTRODUCTION

Regenerative treatment applied to bone trauma depends on the nature of the medical implants used. Large bone defects, osteomyelitis, tumor resection, or skeletal abnormalities can affect normal bone healing. Numerous studies on the mechanisms of skeletal development, pathophysiology and fracture correction have provided important information for establishing methods for regulating the proliferation and differentiation of osteoblasts in the process of bone regeneration (Charoenlarp et al., 2017).

Biomaterials covering medical implants are in a wide range and represent a promising approach that offers a favorable effect in case of bone damage requiring their use. The basic support of implants is Titanium, which is treated with

growth factors to ensure better integration into the body.

Our study involved testing Titan implants treated with Poly (3-hydroxybutyric acid-3-hydroxyvaleric acid) polymer microspheres enriched with fibroblast growth factor 2, vascular endothelial growth factor and bone morphogenetic protein 4 (VGF2) of rats, compared to untreated implants. Fibroblast growth factor 2 (FGF2) is the most common ligand of fibroblast growth factors used in regenerative medicine being an endogenous, positive regulator of bone mass (Fei et al., 2011), which stimulates the proliferation of mesenchymal stem cells (Boteanu et al., 2020). Vascular endothelial growth factor together with bone morphogenetic protein also contributes to stimulating the differentiation of

osteoblasts and osteoclasts. (Böhm et al., 2019; Hu, 2016).

MATERIALS AND METHODS

Ethics statement: The animal study was approved by the Ethics Commission of the "Cantacuzino" National Medico - Military Institute for Research and Development (IC) and authorized by the competent authority. The procedures were carried out in accordance with the provisions of EU Directive 63/2010 on compliance with the rules for the care, use and protection of animals used for scientific purposes.

For this study, 20 rats, Wistar, males and females, aged 20 weeks, were used in experiment. The rats were from the laboratory animal farm of IC, Băneasa Animal Facility (SB). They were acclimatized for 5 days, the accommodation being provided in Euro standard Type III cages (425 x 276 x 153 mm) labeled, for each group of 5 rats, arranged in the SB experiment space. Water and food administered ad libitum as well as microclimate conditions (temperature 22-24%, relative humidity 45-65%, cycles of 12 h of light and 12 h of darkness) remained constant throughout the experiment, according to "Guide for the Care and Use of Laboratory Animals".

Only healthy animals were selected, which were not used in previous tests and two groups were formed (Table 1).

Table 1. Allotment of animals

Group	Sub-group	Number of animals	Sex	Tested implant type
1	1a	5	m	Titanium + VGF2
	1b	5	f	
2	2a	5	m	Titanium
	2b	5	f	

Tested implants: Titanium metal bars coated with growth factors and osteogenesis inducers VGF2 and untreated titanium metal bars (1.5 mm length, 1mm diameter).

Procedure: On day 0 of the experiment all animals were weighed and deeply anesthetized with a mixture of Ketamine (75 mg/kg) and Medetomidine (0.5 mg/kg). Preoperative preparation consisted of clipping the hair at the left tibiofemoral and patellofemoral joint and disinfecting the skin with Betadine. After restrain in dorsoventral recumbency on the operating table, periarticular infiltrations with

10% Lidocaine were performed. The actual surgery involved the induction a bone defect at the distal end of the femur. A skin incision was made on the medial parapatellar side, followed by lateral dislocation of the patella and exposure of the femoral condyles. With the limb held in a flexed position, an intercondylar cavity (into trochlear groove) was created by drilling, using a drill with a diameter of 1 mm, under continuous cooling with saline. The test implant (Table 1.) was inserted into the resulting cavity by pressing it.

The patella was repositioned, and the joint capsule was sutured with 4-0 resorbable suture and the skin with 2-0 non-absorbable. After the suture of the surgical wound, Atipamezole i.p. postoperatively, the animals were treated with antibiotics (Enrofloxacin 5 mg/kg, 5 days) and analgesics (Ketofen 5 mg/kg, 3 days).

The monitoring period of the animals was 6 weeks, during it, local and general clinical signs were observed. Hematological examinations were performed at the beginning and end of the study, biochemical, necropsy and histological examinations were performed on day 42.

RESULTS AND DISCUSSIONS

Clinical examination: The groups in which the VGF2-treated implant was tested showed from the first day postoperatively loss of appetite, adynamic and lameness on the operated limb, and in the first 9 days postoperatively, 5 animals (4 males and one female) died, without presenting a direct connection with the implanted device.

The groups with untreated implant had a moderate clinical evolution. In the first seven days after surgery, the rats were adynamic, showed lameness and 2 males who showed prostration, loss of appetite and dehydration, succumbed on day 3.

The survivors had an unfavorable clinical evolution in the first 28 days (prostration, adynamic, limping, swelling of the joint capsule) and in the last 14 days the general condition improved, the limping disappeared, and the animals regained weight loss.

Body weight was monitored by weighing the animals on a RADWANG scale every two weeks, respectively D0, D14, D28, D42. The

animals from sublots 1b and 2b had a weight loss in the first 14 days after implantation, then a constant increase (Figure 1).

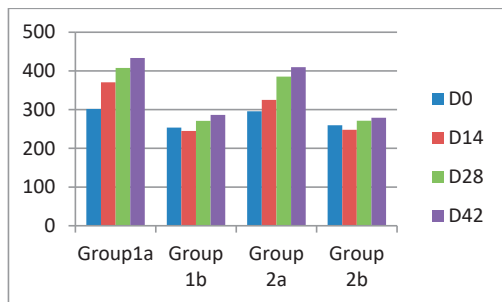


Figure 1. The evolution of body weight

Hematological tests were performed on an Idexx ProCyte 5Diff device, the blood being collected on tubes with EDTA on day 0 and the final day. The mean hematological values obtained on each group are shown in Table 2. Sub-groups 1b, 2b and 2a bis showed increased values of heterocytes and reticulocytes, double that of Z0. The rest of the analyzed parameters did not provide relevant data for our study.

The biochemical analysis was performed on a VetTest 8008 device, and the blood was collected in Li-heparin vacutainers on day 42. The values shown in Table 3 represent the average of the biochemical parameters analyzed in the group where the VGF2-treated implant was mounted and in the group in which the untreated implant was tested.

The values obtained showed marked increases in creatinine and urea, but the correlation with the implanted devices is uncertain because both animals in group 1 and those from group 2 had increased results of the same parameters.

The necropsy was performed for all euthanized animals according to the study protocol and for animals found dead during the experiment. The animals found dead a few days after the operation, did not show changes in the internal organs or in the operated limb, but the poor state of maintenance, severe dehydration could guide the cause of death. Animals that were euthanized at the end of the experiment were in good condition, with no changes in internal organs, and the operated limb was completely healed at both the skin and capsular level.

Table 2. Average hematological parameters

Analyzed Parameter	Group 1a		Group 1b		Group 2a		Group 2b	
	Day 0	Final day	Day 0	Final day	Day 0	Final day	Day 0	Final day
RBCx10 ¹² /L	6.706	7.31	7.58	5.49	6.08	6.38	6.53	6.41
HCT %	33.48	39.08	36.8	29.15	30.02	31.99	31.78	31.94
HGB g/dL	12	13.54	13.34	10.45	10.76	11.51	11.52	11.51
MCV fL	49.78	53.46	48.6	52.8	49.34	50.24	48.34	49.86
MCH, pg	17.94	18.56	17.62	19	17.72	18.11	17.78	18.04
MCHC g/dL	36.08	34.72	36.28	36.02	35.94	36.08	36.8	36.22
RDW %	20.78	24.54	19.18	17.27	20.38	18.94	17.82	18.72
%RETIC	7.3	7.42	2.94	4.22	7.16	4.77	2.8	4.38
RETIC K/ μ L	498.96	546.44	221.08	228.05	430.56	293.23	180.58	270.7
WBCx10 ⁹ /L	8.176	8.28	6.16	6.04	7.2	6.46	4.92	6.16
%HETERO	36.28	26.44	15.24	35.6	38.84	29.89	18.7	27.65
%LYM	53.58	65.32	79.32	57.25	53.98	63.51	73.18	65.44
%MONO	6.16	7.5	4.06	6.12	5.32	5.16	6	5.33
%EOS	3.1	0.36	1.08	1.02	1.46	1.18	1.9	1.33
Analyzed Parameter	Group 1a		Group 1b		Group 2a		Group 2b	
	Day 0	Final day	Day 0	Final day	Day 0	Final day	Day 0	Final day
%BASO	0.88	0.38	0.3	0	0.4	0.23	0.22	0.23
HETEROx10 ⁹ /L	3.058	2.18	0.95	2.57	2.81	2.11	0.91	1.87
LYMx10 ⁹ /L	4.304	5.42	4.87	2.87	3.88	3.87	3.60	3.82
MONOx10 ⁹ /L	0.528	0.60	0.25	0.50	0.37	0.37	0.30	0.36
EOSx10 ⁹ /L	0.212	0.03	0.07	0.09	0.10	0.08	0.09	0.09
BASOx10 ⁹ /L	0.074	0.03	0.01	0	0.03	0.01	0.01	0.01
PLT,K/ μ L	454.4	228	576.6	1002	272	616.86	229.2	539.33
MPV,fL	9.42	10.02	8.3	10.62	8.85	9.25	8.98	9.20
PDW,fL	8.15	7.4	8.4	8.15	7.3	7.95	7.9	7.94
PCT%	0.4	0.20	0.45	0.43	0.28	0.39	0.18	0.34

Table 3. Average of biochemical parameters

Analyzed Parameters	MU	Group with implant treated with VGF2	Reference interval	Group with untreated implant
GLU	mmol/L	9.2	2.78-7.51	7.53
CREA	μmol/L	108.25	9.00-53	115
UREA	mmol/L	7.875	3.2-7.5	8.25
TP	mmol/L	2.6575	1.33-2.90	2.54
CA	g/L	55.25	53-69	49.5
ALB	g/L	31.75	38-48	27.5
GLOB	g/L	23.75	15-28	21
ALT	U/L	44.75	20-61	59
ALKP	U/L	89.5	16-302	77.5
GGT	U/L	0	1.00-6.00	0
TBIL	μmol/L	< 2	2.00-12	2
AMYL	U/L	1232.5	326-2246	1259
LIPA	U/L	91.25	10-150	80.5

The groups with treated VGF2 implant were characterized by the presence of neoformation cells (2-3 rows), moderate fibrosis, proliferation of osteoblasts, homogeneous periosteum and new capillaries (Figure 2), and the groups with untreated implant showed necrosis phenomena, layers of cells suggesting bone reactivity to implant, fibrosis, dense collagen fibers, lymphocytes, fibroblasts, lymphocyte granulation tissue (Figure 3).

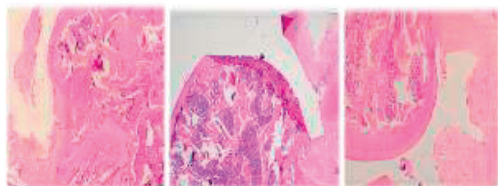


Figure 2. VGF2 implant: ob x 2 H.E., osteoblast proliferation and regeneration phenomena, moderate fibrosis

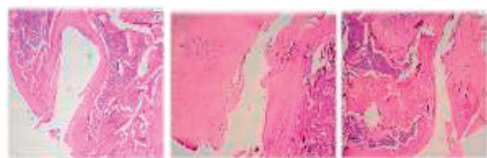


Figure 3. Untreated implant: ob x 2 H.E., necrosis and cells (lymphocytes, fibroblasts) that suggest bone reactivity to the implant

The survival rate was low, especially in the male groups in which the VGF2-treated implant was tested (20%); in subplot 1a, 4/5 rats died approximately 3 days after surgery, with no macroscopically observable clinical signs. Females with VGF2 implants had a survival rate of 71% as did male rats of group 2, in

which untreated implants were fitted. Females in group 2 had a survival rate of 100%.

FGF2, VEGF and BMP4 are widely used for alveolar bone regeneration in the dental field, but it is not clear what growth factor should be recommended for alveolar regeneration. (Charoenlarp, 2017). Most studies have shown that BMP has a higher osteogenic capacity than FGF-2. (Nguyen et al., 2019) Although their application may result in associated complications on different cell types including not only osteoblasts, osteoclasts, but also bone marrow cells and should be studied in more detail to promote more efficient administration of FGF2, VEGF and BMP4. BMP and FGF2-induced bone formation is regulated by bone marrow cells (Nosho et al., 2020), BMP4, on the one hand, promotes bone regeneration and osseointegration around titanium implants, but on the other hand induces bone resorption when a BMP-coated implant it is inserted into a bone such as the mandibular one (Nosho et al., 2020). In long bone fractures, which are abundant sites in the bone marrow, FGF2 significantly accelerated fracture healing and callus formation (Nagayasu-Tanaka et al., 2017; Kawaguchi et al., 2001). BMP is known to stimulate the expression of genes associated with mineralization, but appears to have little or no effect on the expression of genes associated with cell proliferation. FGF-2 is known to be a potent inducer of vascular endothelial growth factor A (Hughes-Fulford, 2011). Furthermore, the effects of FGF-2 on BMP signaling appear to be dose-dependent; While a low dose of FGF-2 could increase BMP-associated bone formation, a high dose of

FGF-2 suppressed it (Kawaguchi et al., 2001). Bone is considered a rigid organ that supports and protects various vital organs in the body, including the bone marrow and the stem cell niche (Abdel Meguid, 2018). In this context, BMP is known to play a key role in the development of hematopoietic bone marrow (Kawai, 1994; Kusumoto, 1995). BMP may be suitable for application in the extramedullary medium, while FGF-2, in medullary bone regeneration.

Vascular endothelial growth factor-A (VEGF) is one of the most important growth factors for regulating vascular development and angiogenesis. Because bone is a highly vascularized organ and angiogenesis plays an important role in osteogenesis, VEGF also influences skeletal development and bone repair (Hu, 2016). During bone development, VEGF is a critical survival factor for epiphyseal chondrocytes so modulating VEGF levels in bones is a potential strategy for treating compromised bone repair and improving bone regeneration (Maes, 2004).

CONCLUSIONS

Despite the low survival rate, which did not show a direct correlation with the placement of the implants, the macroscopic clinical signs reached the proposed objectives, and neoformation bone tissue could be observed around the implant.

The results of the histological examination showed that titanium implants treated with growth factors and inducers of osteogenesis contribute to a faster bone regeneration, and the local effects are favorable.

ACKNOWLEDGEMENTS

This study is part of the Teramed project, PN-III-P1-1.2-PCCDI2017-0728. The authors contributed equally to the experiment. We also thank Mrs. biochemist Gheorghiu Petronica for performing the biochemical and hematological examinations and the veterinarian Ionita Fabiola for the contribution regarding the preoperative preparation of the animals.

REFERENCES

- Abdel Meguid, E., Ke, Y., Ji, J., El-Hashash, A.H.K. (2018). Stem cells applications in bone and tooth repair and regeneration: New insights, tools, and hopes. *J. Cell Physiol.*, 233:1825–1835.
- Boteanu, R. M., Suica, V. I., Ivan, L., Safciuc, F., Uyy, E., Dragan, E., Croitoru, S. M., Grumezescu, V., Chiritoiu, M., Sima, L. E., Vlagioiu, C., Socol, G., Antohe, F. (2020). Proteomics of regenerated tissue in response to a titanium implant with a bioactive surface in a rat tibial defect model. *Sci Rep.*, 10(1):18493.
- Böhm, A. M., Dirckx, N., Tower, R. J., Peredo, N., Vanuytven, S., Theunis, K., Nefyodova, E., Cardoen, R., Lindner, V., Voet, T., Van Hul, M., Maes, C. (2019). Activation of Skeletal Stem and Progenitor Cells for Bone Regeneration Is Driven by PDGFR β Signaling. *Dev Cell.*, 51(2):236-254.
- Charoenlarp, P., Rajendran, A. K., Iseki, S. (2017). Role of fibroblast growth factors in bone regeneration. *Inflamm Regen.*, 37:10.
- Fei, Y., Xiao, L., Doetschman, T., Coffin, D. J., Hurley, M. M. (2011). Fibroblast growth factor 2 stimulation of osteoblast differentiation and bone formation is mediated by modulation of the Wnt signaling pathway. *J Biol Chem.*, 286(47):40575-83.
- Hu, K., Olsen, B. R. (2016). Osteoblast-derived VEGF regulates osteoblast differentiation and bone formation during bone repair. *J Clin Invest.*, 126(2):509-26.
- Hu, K., Olsen, B. R. (2016). The roles of vascular endothelial growth factor in bone repair and regeneration. *Bone*, 91:30-8.
- Hughes-Fulford, M., Li, C. F. (2011). The role of FGF-2 and BMP-2 in regulation of gene induction, cell proliferation and mineralization. *J. Orthop. Surg. Res.*, 6:8.
- Kawaguchi, H., Nakamura, K., Tabata, Y., Ikada, Y., Aoyama, I., Anzai, J., Nakamura, T., Hiyama, Y., Tamura, M. (2001). Acceleration of fracture healing in nonhuman primates by fibroblast growth factor-2. *J. Clin. Endocrinol. Metab.*, 86:875–880.
- Kawai, M., Hattori, H., Yasue, K., Mizutani, H., Ueda, M., Kaneda, T., Hoshino, T. (1994). Development of hemopoietic bone marrow within the ectopic bone induced by bone morphogenetic protein. *Blood Cells.*, 20:191–199.
- Kusumoto, K., Bessho, K., Fujimura, K., Konishi, Y., Ogawa, Y., Iizuka, T. (1995). Comparative study of bone marrow induced by purified BMP and recombinant human BMP-2. *Biochem. Biophys. Res. Commun.*, 215:205–211.
- Maes, C., Stockmans, I., Moermans, K., Van Looveren, R., Smets, N., Carmeliet, P., Bouillon, R., Carmeliet, G. (2004). Soluble VEGF isoforms are essential for establishing epiphyseal vascularization and regulating chondrocyte development and survival. *J Clin Invest.*, 113:188–199.
- Nagayasu-Tanaka, T., Nozaki, T., Miki, K., Sawada, K., Kitamura, M., Murakami, S. (2017). FGF-2 promotes initial osseointegration and enhances stability of

- implants with low primary stability. *Clin. Oral Implant. Res.*, 28:291–297.
- Nguyen, H. T., Ono, M., Oida, Y., Hara, E. S., Komori, T., Akiyama, K., Nguyen, H. T. T., Aung, K. T., Pham, H. T., Tosa I., et al. (2019). Bone Marrow Cells Inhibit BMP-2-Induced Osteoblast Activity in the Marrow Environment. *J. Bone Miner Res.*, 34:327–332.
- Nosho, S., Tosa, I., Ono, M., Satoshi Hara, E., Ishibashi, K., Mikai, A., Tanaka, Y., Kimura-Ono, A., Komori, T., Maekawa, K., Kuboki, T., Oohashi, T. (2020). Distinct Osteogenic Potentials of BMP-2 and FGF-2 in Extramedullary and Medullary Microenvironments. *Int J Mol Sci.*, 21(21):7967.