

CLINICAL AND THERAPEUTIC ASPECTS IN SOME SKIN DISEASES IN DOGS AND CATS

Maria CRIVINEANU¹, Florin Mihai PALAMARU², Valentin NICORESCU¹

¹University of Agronomic Sciences and Veterinary Medicine of Bucharest,
59 Marasti Blvd, District 1, 011464, Bucharest, Romania, Email: maria_crivineanu@yahoo.com,
valinicorescu@yahoo.com

²Kingdom of Animals, Veterinary Services, 29-31 Panduri Street,
District 5, Bucharest, Romania, Email: florinmihai.palamaru@gmail.com

Corresponding author email: maria_crivineanu@yahoo.com

Abstract

In veterinary medicine, skin diseases, regardless of their etiology, record an increased frequency, mostly because humans are sharing the same lifestyle with their quadrupeds. The purpose of this paper was to present the evolution of skin pathology in dogs and cats, in conjunction with the reactivity of the body towards the pathogenic germs also towards the conditioning or opportunistic pathogens. For the identification and diagnosing of dermatitis, in a private veterinary clinic there were examined 18 animals (12 dogs and 6 cats), which showed skin lesions and intense itching. There were diagnosed 5 cases of dermatitis with parasitic etiology, 7 cases of allergic dermatitis (of which 2 cases showed secondary bacterial otitis), 1 case of autoimmune etiology and 5 cases of infectious etiology. In the case of bacterial dermatitis, good results were obtained with treatments based on antibacterials selected by antibiogram, with antipruritic substances, and topical therapeutic baths. Bacteriological examination on special culture media revealed the presence of mainly Staphylococcus species in the pathological material collected from the skin lesions. In the case of parasitic dermatitis, favourable results were obtained by applying spot-on pipettes containing Moxidectin and by administering oral or otic Ivermectin. In allergies, the treatment was effective after allergen elimination, administration of antipruritic substances, followed by therapeutic baths to ensure decontamination of body surface area.

Key words: dermatitis, food allergy, antibiotics, Staphylococcus, demodicosis.

INTRODUCTION

Since ancient times, the pharmacy and therapeutics played a very important role in the evolution of human civilization, meaning about seven thousand years of searching, research and enhancement of products of vegetal, animal and chemical origin, all in the service of life itself. Mankind has always tried to find remedies and with the aid of pharmacology it managed to fight these diseases, thereby restoring the health of animals.

Nowadays, the pharmacy is leading a struggle to adapt to the current pathology and is designed to be up to date with it by finding and establishing specific remedies.

In veterinary medicine, skin diseases, regardless of their etiology, record an increased frequency, mostly because humans are sharing the same lifestyle with their quadrupeds. Thus, a particularly complex issue is the diagnosis and indication of a corresponding pharmaco-

logical therapy for these kinds of disorders (Guaguere et al., 2008; Koch et al., 2012).

The purpose of this paper was to present the evolution of skin pathology in dogs and cats, in conjunction with the reactivity of the body towards the pathogenic germs also towards the conditioning or opportunistic pathogens. The diagnostic methods are very important, without them couldn't be possible to develop a topical or systemic treatment (Miller et al., 2013).

MATERIALS AND METHODS

For the identification and diagnosing of dermatitis, in a private veterinary clinic there were examined 18 animals (12 dogs and 6 cats), which showed skin lesions and intense itching. During the dermatological examination, the sequence of the work methods included the following:

a) recording the history data related to the disease, treatments previously performed

and their results, along with information about the animal's lifestyle;

- b) the dermatological examination that allows the localization and sets the injuries' appearance;
- c) examination using Wood lamp;
- d) sampling for direct microscopic examination;
- e) sampling for inoculation on appropriate medium cultures;
- f) presumptive clinical diagnosis (Rhodes and Werner, 2011).

Depending on the case, in order to make a definite diagnosis, the following additional tests were performed:

- lesions' amplification with a magnifier;
- video-otoscopic examination;
- interpreting the trichogram;
- superficial-scrape examination;
- deep-scrape examination;
- otic smears examination, direct smears and smears obtained after the aspiration with a fine needle;
- scotch test.

In order to identify the bacteria and fungi grafted on the skin, they were inoculated on specific culture mediums. Afterwards, using these cultures, the sensitivity of isolated

bacterial strains to various antibiotics products was tested.

In case of food allergy, the trial consisted of two steps: using a hypoallergenic diet and afterwards a food rechallenge (Cosgrove et al., 2015). The exclusion diet involved feeding the animal a new food that has not been used before, in order to identify the food components that caused an allergic response (Guaguere et al., 2008).

Depending on the situation, intradermal testing, serological testing, patch testing, and skin biopsy were performed.

RESULTS AND DISCUSSIONS

The analysis of the results presented in Table 1 shows that in the 18 cases, analysed for finding the etiologic diagnosis, there were diagnosed 5 cases of dermatitis with parasitic etiology, 7 cases of allergic dermatitis (of which 2 cases showed secondary bacterial otitis), 1 case of autoimmune etiology and 5 cases of infectious etiology (Figure 1).

In addition to primary typical infections, in 12 cases the bacterial infections were secondary.

Table 1. Patients included in study: species, breed, age, sex, diagnosis, healing time

Case no.	Species Breed	Age Sex	Diagnosis		Healing time	
			Primary	Secondary	Primary	Secondary
1	Feline/European	11 years, (F)	Food allergy	Superficial pyoderma	4 months	2 months
2	Feline/European	4 years, (F)	Food allergy	Superficial pyoderma	4 months	2 months
3	Canine/Half-breed	4.5 years, (M)	Discoid lupus erythematosus	Superficial pyoderma	-	2 weeks
4	Canine/Labrador	10 months, (F)	Generalized demodicosis	Deep pyoderma	4 months	1.5 months
5	Canine/Westie	2 years, (M)	Atopic dermatitis	Superficial pyoderma Otitis	-	1 month
6	Canine/Amstaff	10 months, (M)	Atopic dermatitis	Superficial pyoderma	-	3 weeks
7	Canine/Bichon	10 months, (F)	Generalized demodicosis	Superficial pyoderma	10 months	3 months
8	Canine/Chow -Chow	4 years, (M)	Sarcoptic mange	Superficial pyoderma	7 months	2 months
9	Canine/Akita Inu	4 years, (M)	Superficial pyoderma	-	2 weeks	-
10	Canine/Westie	5 years, (M)	Generalized demodicosis	Deep pyoderma	6 months	2 months
11	Feline/European	7 years, (F)	Deep pyoderma	-	1 month	-
12	Canine/Bucovina Shepherd	5 years, (F)	Deep pyoderma	Lick granuloma	2 months	1.5 months
13	Canine/Half-breed	7 years, (F)	Deep pyoderma	Lick granuloma	1 month	1.5 months
14	Feline/European	10 months, (F)	Ear mites	-	2 weeks	-
15	Feline/European	6 years, (F)	Flea saliva allergy	Superficial pyoderma	1 month	2 weeks
16	Feline/Persian	11 years, (M)	Food allergy	Superficial pyoderma	4 months	2 months
17	Canine/German Shepherd	3 years, (M)	Deep pyoderma	-	1 month	-
18	Canine/Mops	4.5 years, (M)	Food allergy	Deep pyoderma Otitis	4 months	2 months 1 month

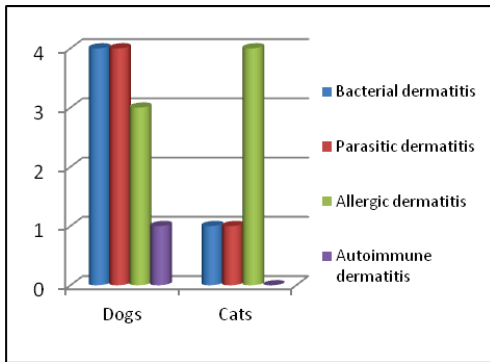


Figure 1. Types of dermatitis in dogs and cats included in the study

Antipruritic therapy was administered in two ways: for a few days to improve the quality of the patients' life or during the whole period of hypoallergenic diet (in case of patients with food allergies), excepting the last 14 days, to see if the remission of itching was present

(Table 2). In the cases with atopic dermatitis, the antipruritic therapy can be applied lifelong, at a minimum dose.

The antibiotic therapy in dermatology is administered for at least 14 days in an infected surface, sometimes reaching 2-3 months in a deep infection. It is necessary to continue the antibiotic treatment for another week after healing of the lesions.

In the case of food allergies, good results were observed after food diets with cooked food which has not been used before, this type of diet being more appropriate than the commercial food because it has no additives and the risk of contamination is low.

Atopic dermatitis has been studied in 2 dogs with different breeds and ages. In order to establish the diagnosis, the animals were subjected to intradermal testing after eliminating the suspicion of food allergy.

Table 2. Treatments administered to patients involved in the study

Case no.	Antibiotherapy	Antipruritic	Antiparasitic	Topical	Diet	Others
1	Cefovecin	Prednisone	Moxidectin	Chlorhexidine	Cooked food	-
2	-	Prednisone	Moxidectin	Chlorhexidine	Cooked food	Hydrocortisone aceponate
3	Marbofloxacin	Methylprednisolone	-	Sunscreen cream	-	Azathioprine (Imuran)
4	Cefalexine	-	Moxidectin Ivermectin	Benzoyl peroxide	-	Allerderm
5	Pradofloxacin	Oclacitinib (Apoquel)	Spinosad (Comfortis)	Chlorhexidine	Cooked food	Itraconazole Vetoskin Allerderm
6	Cefalexine	Oclacitinib	Flumethrin/ Imidacloprid	Chlorhexidine	RC Anallergenic	Immunotherapy Immunotherapy
7	Amoxicillin and clavulanic acid	-	Moxidectin Ivermectin	Benzoyl peroxide	-	Vetoskin
8	Cefalexine	-	Moxidectin	Chlorhexidine	-	Vetoskin
9	Cefalexine	Methylprednisolone	Fipronil	Chlorhexidine	Purina HA	-
10	Ciprofloxacin	-	Moxidectin Ivermectin	Benzoyl peroxide Betadine Mibazon	-	Vetoskin
11	Amoxicillin and clavulanic acid	-	Moxidectin	Chlorhexidine	Purina HA	-
12	Ciprofloxacin	-	-	Chlorhexidine Betadine Mibazon	-	-
13	Cefalexine	-	-	Chlorhexidine Betadine Mibazon	-	-
14	-	-	Ivermectin	EpiOtic	-	-
15	-	Prednisone	Moxidectin	Chlorhexidine	Cooked food	-
16	Pradofloxacin	Prednisone	Moxidectin	Chlorhexidine	Cooked food	Allerderm
17	Cefalexine	Methylprednisolone	-	Chlorhexidine	-	-
18	Marbofloxacin	Oclacitinib	Spinosad	Chlorhexidine EpiOtic EasOtic	Cooked food	Allerderm

Allergy to flea saliva is easy to treat, external monthly disinfection with antiparasitic substances being enough, this way the suspicion of a new reinfestation can be eliminated (Bowman, 2014). Pruritus was partially controlled by the use of antipruritic substances, especially at the beginning of the disease.

Of the 5 cases of parasitic etiology, three dogs showed generalized demodicosis with intercurrent pyoderma. Demodicosis particularly affects dogs between of 3 and 8 month of age, but it was also found in a dog of 5 years age (Mueller et al., 2012). The treatment of generalized canine demodicosis lasted between 4 and 10 months. Good results were obtained using moxidectin spot-on pipettes that had acted as induction followed by administration of ivermectin till the second negative control. The treatment was completed with therapeutic baths based on benzoyl peroxide which had the role of follicular cleaning and bacterial decontamination.

When treating sarcoptic mange, good results were obtained by applying spot-on pipettes based on moxidectin and the bacterial skin infection was treated with systemic antibiotic therapy, topical antibiotic therapy and therapeutic baths with chlorhexidine.

The cat that had ear mites was treated with ivermectin. Good results were obtained after two weeks of treatment, and to prevent bacterial or fungal infections, antiseptic solutions were applied in the ears.

In the case of autoimmune dermatitis, lesions were strictly located on the face and have worsened during the summer due to UV radiation (Day, 2012).

From the skin lesions, *Staphylococcus* species were mainly isolated, but also *Escherichia coli* and *Streptococcus* (Table 3).

Table 3. The results of bacteriological/fungal exams and the sensitivity to antibacterials

Case no.	Bacterial culture	Antibiogram (sensitivity)	Fungal culture
4	<i>Staphylococcus spp</i>	Cefalexine	-
5	<i>Staphylococcus spp</i>	Pradofloxacin	-
8	<i>Staphylococcus spp</i>	Cefalexine	-
9	<i>Staphylococcus spp</i>	Cefalexine	-
10	<i>Staphylococcus spp; E. coli</i>	Ciprofloxacin	Negative
11	-	-	Negative
12	γ and β -hemolytic <i>Streptococcus</i>	Ciprofloxacin	-
13	<i>Staphylococcus spp</i>	Cefalexine	-
16	<i>Staphylococcus spp</i>	Pradofloxacin	-
18	<i>Staphylococcus spp</i>	Marbofloxacin	-

CONCLUSIONS

Of the 18 cases of dogs and cats diagnosed with dermatitis, 38.9% had allergic etiology, 27.8% had bacterial etiology, 27.8% had parasitic etiology and 5.5% had autoimmune etiology.

In the case of bacterial dermatitis, good results were obtained with treatments based on antibacterials selected by antibiogram, with antipruritic substances, and topical therapeutic baths. Bacteriological examination on special culture media revealed the presence of mainly *Staphylococcus* species in the pathological material collected from the skin lesions.

Parasitological examination revealed the presence of Demodex, Sarcopes, and Otodectes parasites. In the case of parasitic dermatitis, favourable results were obtained by applying spot-on pipettes containing Moxidectin and by administering oral or otic Ivermectin.

In allergies, the treatment was effective after allergen elimination, administration of antipruritic substances, followed by therapeutic baths to ensure decontamination of body surface area.

REFERENCES

- Bowman D.D., 2014. Georzi's parasitology for veterinarians, 10th Edition. Elsevier Publishing House, USA.
- Cosgrove S.B., Cleaver D.M., King V.L., Gilmer A.R., Daniels A.E., Wren J.A., Stegemann M.R., 2015. Long-term compassionate use of oclacitinib in dogs with atopic and allergic skin disease: safety, efficacy and quality of life. *Vet. Dermatol.*, 26(3): 171-179.
- Day M.J., 2012. *Clinical Immunology of the Dog and Cat*, 2nd Edition. Manson Publishing House, UK.
- Guaguere E., Prelaud P., Craig M., 2008. *A practical guide to canine dermatology*. Kaliaxis Publishing House, Paris.
- Koch S.N., Torres S.M.F., Plumb D.C., 2012. *Canine and feline dermatology drug handbook*. Wiley-Blackwell Publishing House, Iowa, USA.
- Miller Jr. W.H., Griffin C.E., Campbell K.L., 2013. *Muller & Kirk's Small Animal Dermatology*, 7th Edition. Elsevier Publishing House, Missouri, USA.
- Mueller R.S., Bensignor E., Ferrer L., Holm B., Lemarie S., Paradis M., Shipstone M.A., 2012. Treatment of demodicosis in dogs: 2011 clinical practice guidelines. *Veterinary Dermatology* vol. 23(2): 86-96.
- Rhodes K.H., Werner A.H., 2011. *Blackwell's Five-Minute Veterinary Consult Clinical Companion: Small Animal Dermatology*, 2nd Edition. Wiley-Blackwell Publishing House, Iowa, USA.