

ACTION OF *VARROA DESTRUCTOR* ECTOPARASITE ON EXTERNAL MORPHOLOGY OF THE BEE

**Răzvan-Marius VLĂGIOIU¹, Nicolae CORNILĂ¹, Gabriela CHIOVEANU²,
Florica BARBUCEANU²**

¹University of Agronomic Sciences and Veterinary Medicine of Bucharest,
59 Mărăști Blvd, District 1, 011464, Bucharest, Romania

²Institute of Diagnostic and Animal Health (IDAH), Bucharest, Romania

Corresponding author email: razvanvlagioiu@yahoo.com

Abstract

The work aims to investigate the histological changes produced by the parasite Varroa destructor in bee species Apis mellifera, using as a liquid fixative Dubosq-Brasil and Masson modified coloration.

Key words: *Varroa destructor, malformations, bees.*

INTRODUCTION

Depopulation of bee colonies affected by *Varroa destructor* is a complex phenomenon that draws important economical loss (De Jong, 1997). Parasitization of colonies with *Varroa* have as direct consequence the nympe's death or the loss of viability of eclosionating bees (Kelly et al., 2010). As well, when the parasite affects over 30% of adult bees and drones population, inside the colony, individuals with malformation of wings, members, abdomen and thorax start to appear and also young individuals with unfolding wings after hatching (Rosenkranz, and Engels, 1994, Rosenkranz et al, 2010, Guzman-Novoa et al., 1998).

MATERIALS AND METHODS

Initially, the aim was to realise the histopathological examination on alive bees probes in order to observe tissue modifications as consequence of viral pathogens agents possible transferred by *Varroa destructor*.

In order to determinate the existent structural modifications of intestinal epithelium consecutive hemolymph depletion produced by parasitism with *Varroa destructor*, there has been created a probe stamp with live bees gathered from study apiary, respective experimental apiary of IDAH and have been created two samples, group I that consists in bees clinically healthy, where parasitological, bacteriological and mycological examinations,

didn't evidenced the evolution of specifically disease and group II which consisted in bees from colonies with *Varroa* disease.

The samples have been obtained at the end of active season, in October 2012. Every sample, for each Apiary consists in 25 g alive adult bees parasitized by *Varroa destructor*. For sample creating have been selected bees which has inserted 1-2 *Varroa* parasites between abdominal tergites, and one of them presents wings malformations or small abdomen.

All bees in the Group II were from honeybee colonies that had isolated brood cells presenting irreversible changes in physical characteristics, of the nymphs and the hatching of bees. Some bees found at hatching and expressed nervous syndrome by shaking the wings.

Digestive system samples collected from bees belonging to consignment, have been fixed in the effectiveness of the jumpers: formalin, Dubosq-Brasil, Carnoy and Lille and at the optimal time interval, i.e. at least 72 hours.

All histologic preparations were examined from permanent optical microscope Zeiss, with magnification power of 150 X to X 1250, transmitted light with AxioVision system for capturing microscopic and computational processing them with IDAH: license 'Zeiss Axioplan 2 Image'.

Stage of dehydration and pre including the paraffin were done automatically with a Pathcentra device, and inclusion in paraffin

wax of anatomical parts was also automatically done with Kunz W – 4.

In order to obtain t has been used he microtomical sections Finesse microtome , for laying them, thermostatically controlled bath Kunz set at 40 ° C and a hob with electronic adjustment.

Fixed anatomical pieces were processed and analyzed in the IDAH Laboratory of Pathology and Health of Useful Insects.

Dubosq- Brasil – mixture consists of picric acid: 0.5 g, 75 ml of 80°C.

Formalin - fixed tissues as a result of the completion of the metilenisation processes and dehydration. It is known as the most widespread and efficient fixative for all types of animal tissues, of the species of mammals, birds, reptiles and fish.

Formalin is used in aqueous solutions of 10%.

Carnoy-mixture consists of: 120 ml 60 ml absolute alcohol, chloroform, 20 ml glacial acetic acid.

Lillie mixture – is made up of: 85 ml absolute ethyl alcohol:10 ml formaldehyde 40%, 5 ml glacial acetic acid.

Taking into account the particularities of the structure of the digestive system from bees, as well as the character of sporozoa and oxyphil of viral image inclusions intended to be outlined in the fasteners operation follow the following conditions:

Fixing of parts of the digestive system's of honey bees (gut, gut the environment together with the insertion of Malpighi tubes and posterior intestine) has been carried out immediately after the harvesting a span of 15 minutes;

The ratio of the liquid Fixer and anatomical parts was at least 1/20 and 1/40.

RESULTS AND DISCUSSIONS

Histological preparations, in a first stage were examined at different grosismsents X 100; X 200; X and 1000 X 1200. He showed up as a result of normal small bowel structure clamps at healthy bees from I.

Subsequently, we analyzed the changes produced in the digestive tract and renal Malpighi, depletion of hemolymph caused parasitism with *Varroa destructor*.

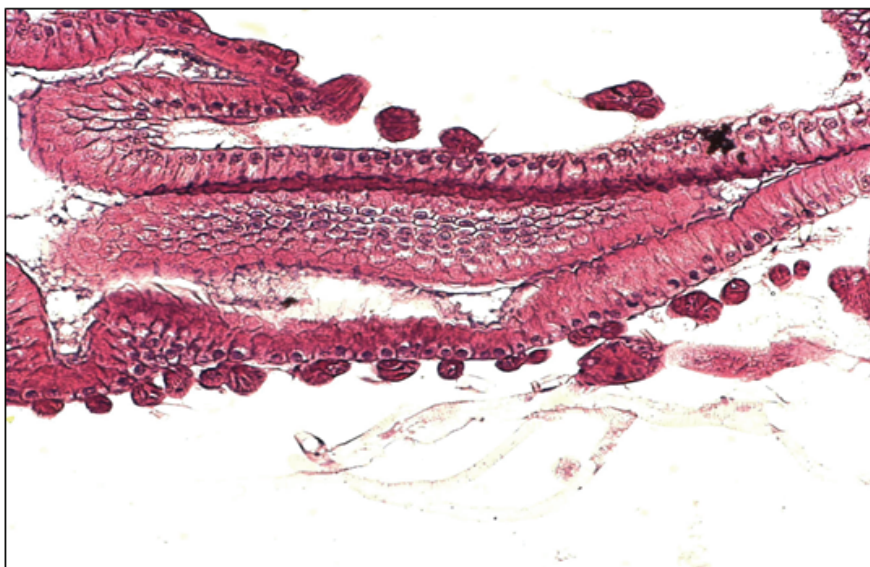


Figure 1. Medium intestine (detail), the adult bee. Masson, with modified method in liquid Dubosq-Brasil x 200 (original)

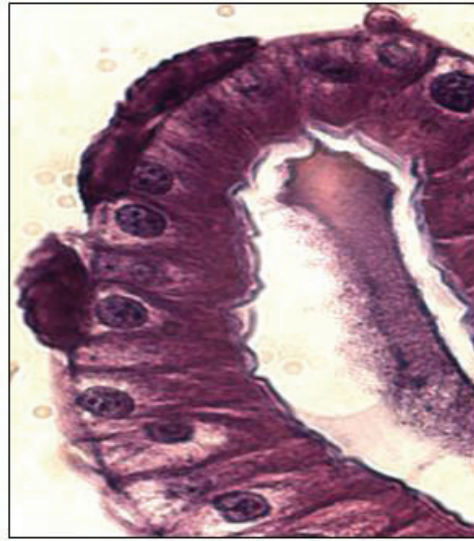

Figure 2. Intestinal anca, adult bee (detail). Masson, with modified method in liquid Dubosq-Brasil, x 1200, NG (original)

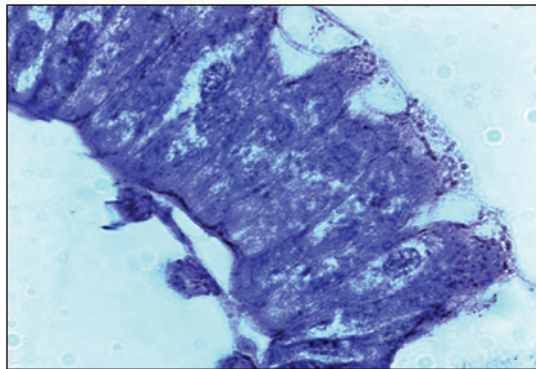


Figure 3. Microvacuolizations, lysis apical cytoplasm in the epithelial cells of the small intestine. Masson, modified method with acid, formalin fixation in X 1000 (original)

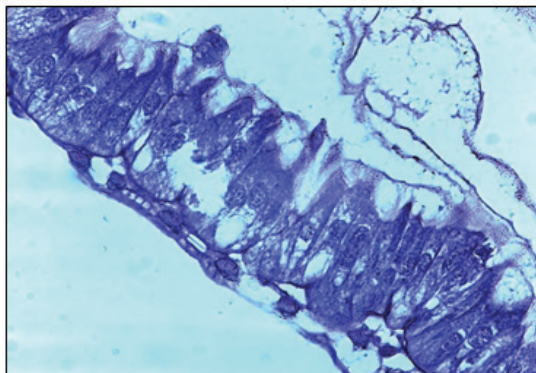


Figure 4. Vacuolizations and intracytoplasmic parasitism and apical destructions of epithelial cells, small intestine-adult bee. Masson, with modified method of fixation in formalin, acid X 1000. (original)

CONCLUSIONS

It has been noticed that hemolymph depletion and virus inoculation develop external morphologic modifications of nymphs and hatched bees.

These modifications appear in abdominal and wings level, which make newly hatched individuals not to be viable. The colony depopulation is occurring step by step following the decrease of newly hatched viable bees.

ACKNOWLEDGEMENTS

This paper was been cofinanced from European Social Fond through Sectorial Operational Program for Human Resources Development 2007 – 2013, Project POS-DRU/107/1.5/S/76888, ' Doctoral bourses for

helping and exploring in agronomical and veterinary medicine field'.

REFERENCES

- De Jong D. (1997). Mites: Varroa and other parasites of brood. pp 278-327. In Honey Bee Pests, Predators, and Diseases (Third Edition). The A.I. Root Company, Medina, Ohio,
- Guzman-Novoa E, Eccles L, Calvete Y, McGowan J, Schmid-Hempel P. (1998). Parasites in Social Insects. Princeton University Press, Princeton, NJ. 410 pp.
- Kelly PG, et al. (2010) Varroa destructor is the main culprit for the death and reduced populations of overwintered honey bee (*Apis mellifera*) colonies in Ontario, Canada. *Apidologie* 41: 443–450,
- Rosenkranz P, Aumeier P, Ziegelmann B (2010) Biology and control of Varroa destructor. *Journal of Invertebrate Pathology* 103: S96–S119,
- Rosenkranz, P., and W. Engels. (1994) Infertility of Varroa jacobsoni females after invasion into *Apis mellifera* worker brood as a tolerance factor against varroaosis. *Apidologie* 25: 402D411.